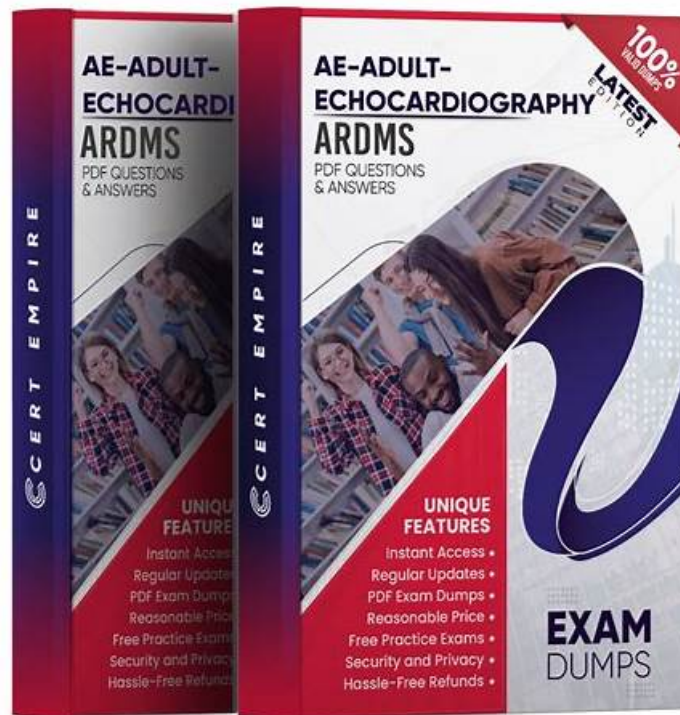


ARDMS AE-Adult-Echocardiography Braindumps Torrent, Simulations AE-Adult-Echocardiography Pdf



On the one hand, according to the statistics from the feedback of all of our customers, the pass rate among our customers who prepared for the exam with the help of our AE-Adult-Echocardiography guide torrent has reached as high as 98% to 100%. On the other hand, the simulation test is available in our software version, which is useful for you to get accustomed to the AE-Adult-Echocardiography Exam atmosphere. Please believe us that our AE-Adult-Echocardiography torrent question is the best choice for you.

ARDMS AE-Adult-Echocardiography Exam Syllabus Topics:

Topic	Details
Topic 1	<ul style="list-style-type: none"> Anatomy and Physiology: This section of the exam measures skills of adult echocardiography technicians and covers knowledge and abilities related to normal cardiac anatomy and physiology. It includes assessing great vessels like the aorta and pulmonary arteries, recognizing anatomic variants of the heart, and evaluating cardiac chambers, pericardium, valve structures, and vessels of arterial and venous return. Candidates must document normal systolic and diastolic function, normal valve function and measurements, the phases of the cardiac cycle, normal Doppler changes with respiration, and appearance of arterial and venous waveforms. This also involves assessing the normal hemodynamic response to stress testing and maneuvers such as Valsalva, respiratory, handgrip, and postural changes.
Topic 2	<ul style="list-style-type: none"> Clinical Care and Safety: This section of the exam measures skills of adult echocardiography technicians in applying clinical care principles and safety protocols. It includes evaluating patient history and external data, preparing patients including fasting state and intravenous line management, proper patient positioning, EKG lead placement, blood pressure measurement, and ergonomic techniques. Candidates are expected to identify critical echocardiographic findings, know contraindications for procedures, and be able to respond and manage medical emergencies that may arise during echocardiographic exams.

Topic 3	<ul style="list-style-type: none"> • Pathology: This section of the exam measures skills of adult echocardiography technicians and focuses on identifying and evaluating abnormal physiology and perfusion and postoperative conditions. It includes assessment of ventricular aneurysms, aortic and valve abnormalities, arrhythmias, cardiac masses, diastolic dysfunction, endocarditis, ischemic diseases, cardiomyopathies, congenital anomalies, and postoperative valve repair or replacement and intracardiac devices. Candidates must demonstrate ability to recognize abnormal Doppler signals, EKG changes, wall motion abnormalities, and a wide range of cardiac pathologies including pulmonary hypertension and septal defects.
Topic 4	<ul style="list-style-type: none"> • Measurement Techniques, Maneuvers, and Sonographic Views: This section of the exam measures skills of adult echocardiography technicians in performing accurate cardiac measurements, conducting provocative maneuvers, and obtaining optimized sonographic imaging views. It involves applying 2D, 3D, M-mode, and Doppler techniques to measure heart valves, chambers, and vessels, including the aortic valve, mitral valve, left and right ventricles, atria, pulmonary artery, and shunt ratios. Candidates must instruct patients in maneuvers such as Valsalva, cough, sniff, and squat. They should also be proficient in acquiring standard echocardiographic views including apical, parasternal, subcostal, and suprasternal notch views.
Topic 5	<ul style="list-style-type: none"> • Instrumentation, Optimization, and Contrast: This section of the exam measures skills of adult echocardiography technicians related to use and optimization of ultrasound instrumentation and the application of contrast agents. Candidates should recognize imaging artifacts, utilize non-imaging transducers, and adjust ultrasound console settings for optimal imaging and Doppler recordings. Knowledge of harmonic imaging, principles of contrast agents, and the safe and effective use of saline and echo-enhancing contrast agents is essential. Candidates must also be able to optimize images when using contrast agents to ensure diagnostic quality.

>> ARDMS AE-Adult-Echocardiography Braindumps Torrent <<

Simulations AE-Adult-Echocardiography Pdf | AE-Adult-Echocardiography Latest Dumps Free

In the Desktop AE-Adult-Echocardiography practice exam software version of ARDMS AE-Adult-Echocardiography practice test is updated and real. The software is useable on Windows-based computers and laptops. There is a demo of the AE Adult Echocardiography Examination (AE-Adult-Echocardiography) practice exam which is totally free. AE Adult Echocardiography Examination (AE-Adult-Echocardiography) practice test is very customizable and you can adjust its time and number of questions.

ARDMS AE Adult Echocardiography Examination Sample Questions (Q134-Q139):

NEW QUESTION # 134

Which structure is the arrow pointing to in this video?

- A. Descending aorta
- **B. Coronary sinus**
- C. Left atrial appendage
- D. Left lower pulmonary vein

Answer: B

Explanation:

The arrow points to the coronary sinus, which is a venous structure located posteriorly in the atrioventricular groove, emptying into the right atrium. It appears as a circular anechoic structure near the left atrium in echocardiographic images.

Left lower pulmonary vein enters the left atrium more superiorly. Descending aorta is posterior to the heart but not in this location. Left atrial appendage is an anterior finger-like projection of the left atrium, separate from the coronary sinus.

This anatomy is described in the "Textbook of Clinical Echocardiography, 6e", Chapter on Cardiac Venous Anatomy#20:140-145Textbook of Clinical Echocardiography#.

NEW QUESTION # 135

When utilizing contrast agents, what should the sonographer keep in mind?

- A. The contrast-enhanced exam poses no risk to the patient.
- **B. Anaphylactoid reactions may occur.**
- C. Patients with no history of allergies will not have reactions.
- D. Contrast agents produce only mild reactions.

Answer: B

Explanation:

Contrast agents used in echocardiography can rarely cause anaphylactoid reactions, which are non-IgE-mediated hypersensitivity reactions that can mimic anaphylaxis. Therefore, sonographers must be prepared to manage such reactions.

Contrary to option B, reactions can be severe though rare. Even patients without prior allergies can react. It is incorrect to say the exam poses no risk; proper precautions and monitoring are essential.

These precautions are emphasized in ASE contrast echocardiography guidelines and safety protocols#12:ASE Contrast Echocardiography Guidelinesp.190-195##16:Textbook of Clinical Echocardiography, 6ep.575-580#.

NEW QUESTION # 136

Which structure is indicated by the arrow on this image of a normal valve?

- A. Non-coronary cusp
- **B. Left coronary cusp**
- C. Septal leaflet
- D. Posterior leaflet

Answer: B

Explanation:

The arrow points to the left coronary cusp of the aortic valve, identifiable in the short axis view as one of the three cusps. The left coronary cusp is adjacent to the left coronary artery origin and lies anteriorly.

The posterior leaflet is part of the mitral valve, septal leaflet refers to the tricuspid valve, and non-coronary cusp is another aortic cusp located posteriorly.

This identification is found in the "Textbook of Clinical Echocardiography, 6e", Chapter on Aortic Valve Anatomy#20:50-55Textbook of Clinical Echocardiography#.

NEW QUESTION # 137

Which wall is indicated by the arrows on this image?

- A. Anteroseptum
- **B. Anterolateral**
- C. Inferoseptum
- D. Inferior

Answer: B

Explanation:

Comprehensive and Detailed Explanation From Exact Extract:

The echocardiographic image shows an apical four-chamber view of the left ventricle. The arrows point to the lateral wall of the left ventricle, which in this view corresponds to the anterolateral wall. The anterolateral wall is located opposite the septum and posterior to the left atrium.

Anteroseptum and inferoseptum refer to different segments of the interventricular septum. The inferior wall is visualized better in other views.

This segmental wall nomenclature and identification are described in ASE chamber quantification and stress echocardiography guidelines#12:ASE Chamber Quantification Guidelinesp.90-95##16:Textbook of Clinical Echocardiography, 6ep.140-145#.

NEW QUESTION # 138

Which finding is associated with partial anomalous venous return?

- A. Perimembranous ventricular septal defect
- B. Cleft mitral valve
- C. Sinus venosus atrial septal defect
- D. Persistent left superior vena cava

Answer: C

Explanation:

Partial anomalous pulmonary venous return (PAPVR) is a congenital defect where some pulmonary veins drain into the right atrium or systemic venous circulation rather than the left atrium. It is frequently associated with sinus venosus atrial septal defect (ASD), a defect near the junction of the superior vena cava and right atrium.

Cleft mitral valve is commonly associated with atrioventricular septal defects. Persistent left superior vena cava is a separate venous anomaly not typically linked with PAPVR. Perimembranous ventricular septal defects are different congenital defects not related to pulmonary venous anomalies.

The association between PAPVR and sinus venosus ASD is well described in the "Textbook of Clinical Echocardiography, 6e", Chapter on Congenital Heart Disease and Shunt Lesions#20:120-130Textbook of Clinical Echocardiography#

NEW QUESTION # 139

.....

The community has a lot of talent, people constantly improve their own knowledge to reach a higher level. But the country's demand for high-end IT staff is still expanding, internationally as well. So many people want to pass ARDMS AE-Adult-Echocardiography certification exam. But it is not easy to pass the exam. However, in fact, as long as you choose a good training materials to pass the exam is not impossible. We ActualTestsIT ARDMS AE-Adult-Echocardiography Exam Training materials in full possession of the ability to help you through the certification. ActualTestsIT website training materials are proved by many candidates, and has been far ahead in the international arena. If you want to through ARDMS AE-Adult-Echocardiography certification exam, add the ActualTestsIT ARDMS AE-Adult-Echocardiography exam training to Shopping Cart quickly!

Simulations AE-Adult-Echocardiography Pdf: <https://www.actualtestsit.com/ARDMS/AE-Adult-Echocardiography-exam-prep-dumps.html>

- 100% Pass AE-Adult-Echocardiography - Latest AE Adult Echocardiography Examination Braindumps Torrent Search for AE-Adult-Echocardiography and obtain a free download on **【 www.examcollectionpass.com 】** Reliable AE-Adult-Echocardiography Exam Bootcamp
- Latest Real AE-Adult-Echocardiography Exam Pass4sure AE-Adult-Echocardiography Study Materials AE-Adult-Echocardiography Reliable Test Preparation Search for **➤ AE-Adult-Echocardiography** on **➡ www.pdfvce.com** immediately to obtain a free download AE-Adult-Echocardiography Exam Passing Score
- Excellent Offers By www.pdfdumps.com – Free ARDMS AE-Adult-Echocardiography Dumps Updates and Free Demo Search for “ AE-Adult-Echocardiography ” and download exam materials for free through www.pdfdumps.com Valid Exam AE-Adult-Echocardiography Blueprint
- Excellent Offers By Pdfvce – Free ARDMS AE-Adult-Echocardiography Dumps Updates and Free Demo Search for **➡ AE-Adult-Echocardiography** and obtain a free download on [www.pdfvce.com] New AE-Adult-Echocardiography Test Book
- AE-Adult-Echocardiography Test Lab Questions - AE-Adult-Echocardiography Latest Exam Topics - AE-Adult-Echocardiography Study Questions Files Search for **➡ AE-Adult-Echocardiography** and obtain a free download on **▶ www.prepawaypdf.com** Frequent AE-Adult-Echocardiography Update
- ARDMS AE-Adult-Echocardiography Exam Questions - Failure Will Result In A Refund Easily obtain **✪ AE-Adult-Echocardiography** for free download through [www.pdfvce.com] AE-Adult-Echocardiography Exam Passing Score
- AE-Adult-Echocardiography Test Lab Questions - AE-Adult-Echocardiography Latest Exam Topics - AE-Adult-Echocardiography Study Questions Files Open **➡ www.examcollectionpass.com** enter **▶ AE-Adult-Echocardiography** and obtain a free download Pass4sure AE-Adult-Echocardiography Study Materials
- Free PDF Trustable AE-Adult-Echocardiography - AE Adult Echocardiography Examination Braindumps Torrent The page for free download of **【 AE-Adult-Echocardiography 】** on **▶ www.pdfvce.com** will open immediately VCE AE-Adult-Echocardiography Dumps
- Excellent Offers By www.easy4engine.com – Free ARDMS AE-Adult-Echocardiography Dumps Updates and Free Demo Search for AE-Adult-Echocardiography and download it for free on “ www.easy4engine.com ” website

☐Frequent AE-Adult-Echocardiography Update

- 100% Pass ARDMS - Reliable AE-Adult-Echocardiography - AE Adult Echocardiography Examination Braindumps Torrent ☐ Enter ☐ www.pdfvce.com ☐ and search for (AE-Adult-Echocardiography) to download for free ☐VCE AE-Adult-Echocardiography Dumps
- ARDMS AE-Adult-Echocardiography Exam Questions - Failure Will Result In A Refund ☐ Simply search for ➡ AE-Adult-Echocardiography ☐ for free download on 「 www.examdiss.com 」 ☐AE-Adult-Echocardiography Top Dumps
- jaspersicu063766.blog5star.com, pageoftoday.com, jimlexd123633.p2blogs.com, www.stes.tyc.edu.tw, honeynplt409394.wikiinside.com, cypriotdirectory.com, isocialfans.com, bookmarkingalpha.com, pennywaii749046.qodsblog.com, idaskja587716.wikiworldstock.com, Disposable vapes