

Latest AE-Adult-Echocardiography Braindumps Questions & AE-Adult-Echocardiography Exam Quick Prep

ADULT ECHOCARDIOGRAPHY EXAM **Questions with 100% Verified Answers** **Latest Version 2025 Graded A+**

A 38-year-old male is taken to the lab for assessment after complaining of severe dyspnea with exertion for two months. M-mode observations include dilated LV, increased E point to septal separation (EPSS), a B-notch on the MV, and hypo contractile LV wall motion. What form of heart problem do these results indicate? - ANSWER Dilated cardiomyopathy.

After a chest x-ray revealed cardiomegaly, a 58-year-old female with a primary symptom of increased dyspnea with exertion is referred for an echo. The echocardiogram shows LV hypertrophy with a "bright" myocardial appearance, LA enlargement, and a modest pericardial effusion. What's the most likely heart diagnosis for this patient? - ANSWER Infiltrative (restrictive) cardiomyopathy.

A 56-year-old female goes to her doctor with a complaint of SOB. Physical examination reveals a low-frequency diastolic (rumbling) murmur. The patient denies any prior history of rheumatic fever. Which three cardiac abnormalities might be present in this patient? - Answer: Mitral stenosis.

- LA Myxomas

- Aortic regurgitation.

A 31-year-old man with a history of uncontrolled systemic hypertension arrives at the emergency room with acute chest pain that he describes as "ripping". What's the most likely heart diagnosis for this patient?

BTW, DOWNLOAD part of Pass4Leader AE-Adult-Echocardiography dumps from Cloud Storage:
https://drive.google.com/open?id=1GEtOFrYmJHa-OW1gHLS_zXH0TJno019C

The AE Adult Echocardiography Examination (AE-Adult-Echocardiography) prep material is available in three versions. AE-Adult-Echocardiography Practice exams and PDF questions are available at Pass4Leader so that users can meet their training needs and pass the AE Adult Echocardiography Examination (AE-Adult-Echocardiography) exam on the first try. The philosophy of Pass4Leader behind offering AE Adult Echocardiography Examination (AE-Adult-Echocardiography) prep material in three formats is helping students meet their unique learning needs.

Perhaps you have also seen the related training tools about ARDMS certification AE-Adult-Echocardiography exam on other websites, but our Pass4Leader has a pivotal position in the field of IT certification exam. Pass4Leader research materials can 100% guarantee you to pass the exam. With Pass4Leader your career will change and you can promote yourself successfully in the IT area. When you select Pass4Leader you'll really know that you are ready to pass ARDMS Certification AE-Adult-Echocardiography Exam. We not only can help you pass the exam successfully, but also will provide you with a year of free service.

>> Latest AE-Adult-Echocardiography Braindumps Questions <<

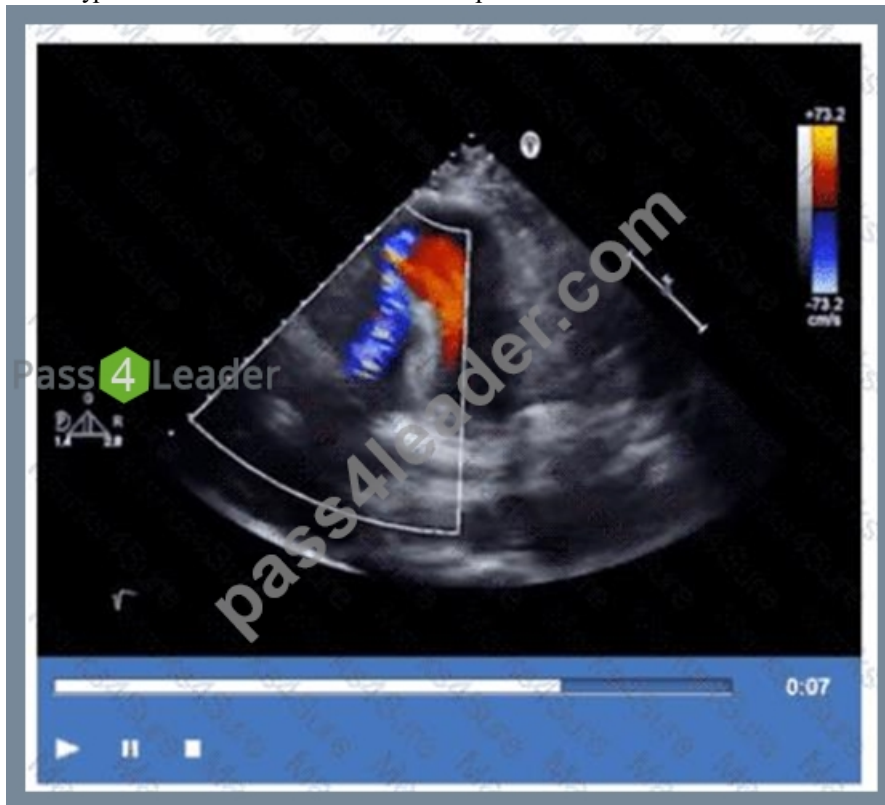Pass Guaranteed 2026 AE-Adult-Echocardiography: AE Adult Echocardiography Examination –Reliable Latest Braindumps Questions

Learning knowledge is not only to increase the knowledge reserve, but also to understand how to apply it, and to carry out the theories and principles that have been learned into the specific answer environment. Studying for attending AE Adult Echocardiography Examination exam pays attention to the method. The good method often can bring the result with half the effort, therefore we in the examination time, and also should know some test-taking skill. The AE-Adult-Echocardiography Quiz guide on the basis of summarizing the past years, found that many of the questions, the answers have certain rules can be found, either subjective or objective questions, we can find in the corresponding module of similar things in common.

ARDMS AE Adult Echocardiography Examination Sample Questions (Q79-Q84):

NEW QUESTION # 79

Which type of defect can be seen in this video clip?



- A. Ischemic ventricular septal defect
- B. Pseudoaneurysm of the apex
- C. Tricuspid regurgitation
- D. Coronary artery aneurysm

Answer: A

Explanation:

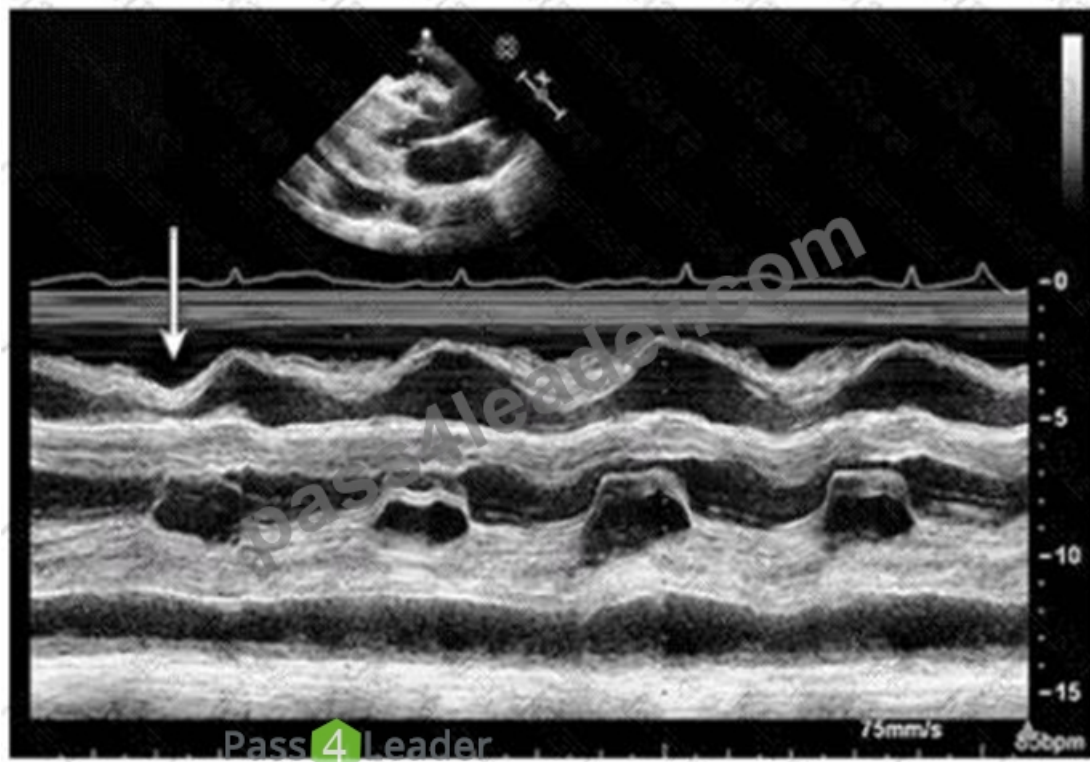
The echocardiographic video shows a defect in the ventricular septum with left-to-right shunting consistent with an ischemic ventricular septal defect (VSD), a mechanical complication of myocardial infarction. The defect allows blood flow between the left and right ventricles.

Coronary artery aneurysm appears as dilated coronary vessels, not a septal defect. Tricuspid regurgitation involves the right atrioventricular valve and is identified differently. Pseudoaneurysm of the apex is a contained myocardial rupture with narrow neck and does not involve septal communication.

This complication and its echocardiographic features are described in the "Textbook of Clinical Echocardiography, 6e", Chapter on Post-Infarction Mechanical Complications#20:430-435Textbook of Clinical Echocardiography#.

NEW QUESTION # 80

Which condition is most plausible based on the finding indicated by the arrow on this image?



- A. Constrictive pericarditis
- B. Cardiac tamponade
- C. Pulmonary hypertension
- D. Pulmonary embolism

Answer: A

Explanation:

The image is a parasternal long axis M-mode echocardiographic tracing demonstrating the interventricular septum and posterior left ventricular wall. The arrow points to the septal "bounce" or "shudder," which is an abnormal early diastolic septal motion. This septal bounce is a classic echocardiographic finding in constrictive pericarditis, caused by rapid early diastolic filling with abrupt cessation due to pericardial constraint, resulting in paradoxical septal motion.

Cardiac tamponade usually shows pericardial effusion with chamber collapse but not septal bounce.

Pulmonary embolism and pulmonary hypertension have different echocardiographic signs such as right ventricular dilatation and pressure overload but no septal bounce.

These features are well described in the "Textbook of Clinical Echocardiography" and ASE pericardial disease guidelines#16:Textbook of Clinical Echocardiography, 6ep.280-285##12:ASE Pericardial Disease Guidelinesp.300-305#.

NEW QUESTION # 81

Sinus of Valsalva aneurysms most commonly rupture into which structure(s)?

- A. Right heart chambers
- B. Coronary sinus
- C. Pericardial space
- D. Left atrium

Answer: A

Explanation:

Sinus of Valsalva aneurysms typically rupture into the right heart chambers, most commonly the right atrium or right ventricle. This creates a left-to-right shunt and can lead to volume overload and heart failure if not treated.

Rupture into the pericardial space is less common and may cause tamponade. Rupture into the left atrium or coronary sinus is rare. This clinical detail is described in the "Textbook of Clinical Echocardiography, 6e", Chapter on Aortic Root Pathology and Sinus of

NEW QUESTION # 82

Which two-dimensional method is recommended for assessing left ventricular ejection fraction when regional wall motion abnormalities are present?

- A. Tetcholz
- B. Visual
- C. Quinones
- **D. Simpson biplane**

Answer: D

Explanation:

The Simpson biplane method (method of disks) is the recommended two-dimensional echocardiographic technique to quantify left ventricular ejection fraction (LVEF), especially when regional wall motion abnormalities are present. It involves tracing endocardial borders in apical two- and four-chamber views to calculate LV volumes and EF, accounting for segmental dysfunction. Visual estimation is subjective and less accurate. The Quinones method (single plane area-length) and Teichholz method rely on geometric assumptions and are less accurate in abnormal ventricles.

ASE chamber quantification guidelines strongly endorse Simpson biplane for LVEF assessment in regional wall motion abnormalities#12:ASE Chamber Quantification Guidelinesp.70-75##16:Textbook of Clinical Echocardiography, 6ep.60-65#.

NEW QUESTION # 83

Which sonographic views allow visualization of a patent ductus arteriosus (PDA)?

- **A. Suprasternal notch and basal parasternal short axis**
- B. Parasternal long axis and apical five-chamber
- C. Parasternal long axis and apical long axis
- D. Basal parasternal short axis and right ventricular inflow tract

Answer: A

Explanation:

Comprehensive and Detailed Explanation From Exact Extract:

Visualization of a patent ductus arteriosus (PDA) typically requires imaging planes that include the aortic arch and pulmonary artery, which are well seen from the suprasternal notch window and the basal parasternal short axis view.

The suprasternal notch window provides a longitudinal view of the aortic arch and adjacent pulmonary artery, where the PDA is located. The basal parasternal short axis at the level of the great vessels can also visualize flow through the PDA using color Doppler.

Other views like parasternal long axis and apical views are less optimal for direct PDA visualization.

This is detailed in the "Textbook of Clinical Echocardiography, 6e", Chapter on Congenital Heart Defects and PDA

Imaging#20:370-375Textbook of Clinical Echocardiography#.

NEW QUESTION # 84

.....

The users can instantly access the product after purchasing it from Pass4Leader AE-Adult-Echocardiography, so they don't have to wait to prepare for the ARDMS AE-Adult-Echocardiography Exams. The 24/7 support system is available for the customers, so they can contact the support whenever they face any issue, and it will provide them with the solution. Furthermore, Pass4Leader offers up to 1 year of free updates and free demos of the product.

AE-Adult-Echocardiography Exam Quick Prep: <https://www.pass4leader.com/ARDMS/AE-Adult-Echocardiography-exam.html>

As they have a good command of trend and key points of the AE-Adult-Echocardiography exam cram, they know more about how to arrange the order of content and how to improve the efficiency of learning. If you don't have time to sit in front of your computer all day but still want to get into some AE Adult Echocardiography Examination (AE-Adult-Echocardiography) exam questions, AE-Adult-Echocardiography PDF format is for you, Our AE-Adult-Echocardiography practice material is a very good test engine,

which can help you broaden your knowledge.

Creating powerful, resilient virtual networks to handle critical storage AE-Adult-Echocardiography network traffic, You will learn how to create and manage documents and edit them on any device, with iCloud keeping the files up to date.

ARDMS AE-Adult-Echocardiography Questions - Exam Success Tips And Tricks

As they have a good command of trend and key points of the AE-Adult-Echocardiography Exam Cram, they know more about how to arrange the order of content and how to improve the efficiency of learning.

If you don't have time to sit in front of your computer all day but still want to get into some AE Adult Echocardiography Examination (AE-Adult-Echocardiography) exam questions, AE-Adult-Echocardiography PDF format is for you.

Our AE-Adult-Echocardiography practice material is a very good test engine, which can help you broaden your knowledge, We check update every day, and if there is any update about the AE-Adult-Echocardiography practice torrent, our system will automatically send email to your payment email.

We can make sure that you will like our products;

- Exam AE-Adult-Echocardiography Answers □ Latest AE-Adult-Echocardiography Exam Pass4sure □ Exam AE-Adult-Echocardiography Answers □ Search for ➡ AE-Adult-Echocardiography □ and download it for free on ➡ www.practicevce.com ⇐ website □ Free AE-Adult-Echocardiography Exam Dumps
- AE-Adult-Echocardiography New Exam Bootcamp □ AE-Adult-Echocardiography Braindump Pdf □ New AE-Adult-Echocardiography Test Simulator □ ➡ www.pdfvce.com □ is best website to obtain ➡ AE-Adult-Echocardiography □ for free download □ Exam AE-Adult-Echocardiography Tutorials
- AE-Adult-Echocardiography Practice Exam Materials: AE Adult Echocardiography Examination and AE-Adult-Echocardiography Study Guide - www.dumpsmaterials.com □ ▶ www.dumpsmaterials.com ◀ is best website to obtain □ AE-Adult-Echocardiography □ for free download □ AE-Adult-Echocardiography Braindump Pdf
- Exam AE-Adult-Echocardiography Tutorials □ AE-Adult-Echocardiography Associate Level Exam □ AE-Adult-Echocardiography Braindump Pdf □ Copy URL ➡ www.pdfvce.com □ open and search for ✓ AE-Adult-Echocardiography □ ✓ □ to download for free □ AE-Adult-Echocardiography Associate Level Exam
- Free AE-Adult-Echocardiography Exam □ New AE-Adult-Echocardiography Exam Guide □ New AE-Adult-Echocardiography Exam Guide □ Search for 「 AE-Adult-Echocardiography 」 and download it for free on 《 www.prep4sures.top 》 website □ Exam AE-Adult-Echocardiography Answers
- 100% Pass 2026 ARDMS Marvelous Latest AE-Adult-Echocardiography Braindumps Questions □ Go to website ☀ www.pdfvce.com □ ☀ □ open and search for 【 AE-Adult-Echocardiography 】 to download for free □ Latest AE-Adult-Echocardiography Exam Questions Vce
- AE-Adult-Echocardiography Practice Exam Materials: AE Adult Echocardiography Examination and AE-Adult-Echocardiography Study Guide - www.examcollectionpass.com □ Simply search for [AE-Adult-Echocardiography] for free download on ▷ www.examcollectionpass.com ◁ □ Reliable AE-Adult-Echocardiography Test Braindumps
- 100% Pass Valid ARDMS - AE-Adult-Echocardiography - Latest AE Adult Echocardiography Examination Braindumps Questions □ Open (www.pdfvce.com) enter ▷ AE-Adult-Echocardiography ◁ and obtain a free download □ Study AE-Adult-Echocardiography Materials
- Free PDF 2026 AE-Adult-Echocardiography: AE Adult Echocardiography Examination –High Pass-Rate Latest Braindumps Questions □ Open website □ www.pdfdumps.com □ and search for ☀ AE-Adult-Echocardiography □ ☀ □ for free download □ Free AE-Adult-Echocardiography Exam
- ARDMS - AE-Adult-Echocardiography - High Hit-Rate Latest AE Adult Echocardiography Examination Braindumps Questions □ Search for □ AE-Adult-Echocardiography □ and download it for free on “ www.pdfvce.com ” website □ AE-Adult-Echocardiography Braindump Pdf
- Free PDF 2026 AE-Adult-Echocardiography: AE Adult Echocardiography Examination –High Pass-Rate Latest Braindumps Questions □ Go to website “ www.dumpsmaterials.com ” open and search for { AE-Adult-Echocardiography } to download for free □ Latest AE-Adult-Echocardiography Exam Pass4sure
- www.stes.tyc.edu.tw, www.stes.tyc.edu.tw, myportal.utt.edu.tt, myportal.utt.edu.tt, myportal.utt.edu.tt, myportal.utt.edu.tt, myportal.utt.edu.tt, myportal.utt.edu.tt, myportal.utt.edu.tt, myportal.utt.edu.tt, myportal.utt.edu.tt, myportal.utt.edu.tt, xpeedupstyor.com, gataxiom19.blogspot.com, lms.ait.edu.za, www.stes.tyc.edu.tw, mindgrafts.com, www.stes.tyc.edu.tw, www.stes.tyc.edu.tw, Disposable vapes

P.S. Free 2026 ARDMS AE-Adult-Echocardiography dumps are available on Google Drive shared by Pass4Leader:
https://drive.google.com/open?id=1GEtOFRYmJHa-OW1gHLS_zXHoTJno019C