

Prepare for the ARDMS AB-Abdomen Exam on Any Device with itPass4sure PDF Format

Preparation for Abdomen ARDMS Exam with Complete Verified Solutions 2024!!

bull's eye sign - Ultrasound appearance of gastroesophageal junction?

rugae - irregular folds in stomach formed by mucosa and submucosal

5 mm's - the undistended wall should not exceed how many mm's

haustreae - what are the large sacculations of the colon called?

thickened loops with no change with compression - slow graded transducer pressure is applied with evaluation of gi tract, what would these findings reveal?

target sign and pseudo kidney sign - what is the classic appearance of adenocarcinoma?

6mm - normal appendix has a target appearance and should not measure more than-----mm in diameter?

adhesions - what is most common cause of intestinal obstruction?

Increased activity - Evaluation of motor activity with obstruction will reveal?

Chronic - Is hashimoto's thyroiditis an acute or chronic condition?

calcium levels - the parathyroid glands secrete PTH which is responsible for maintaining what levels?

Papillary - what is most common type of thyroid cancer?

Increased PTH levels, hypophosphatemia and hypercalcemia - The lab values with parathyroid adenoma's will reveal what?

Longus coli muscle - what is the muscle located posterior to the thyroid and adjacent to the trachea?

External carotid artery - The superior thyroid artery branches off what artery?

Thyroid enlargement, protruding eyeballs - Two features of Grave's disease?

Multinodular Goiter - What is the most common type of thyroid abnormality?

BONUS!!! Download part of itPass4sure AB-Abdomen dumps for free: <https://drive.google.com/open?id=17KigWVoZKjuNZkj-6BITbzRd44YvdUrB>

Our AB-Abdomen guide questions enjoy a very high reputation worldwide. This is not only because our AB-Abdomen practical materials are affordable, but more importantly, our AB-Abdomen useful test files are carefully crafted after years of hard work and the quality is trustworthy. If you are still anxious about getting a certificate, why not try our AB-Abdomen Study Guide? If you have any questions about our AB-Abdomen practical materials, you can ask our staff who will give you help. And we offer considerable services on the AB-Abdomen exam questions for 24/7.

In the past ten years, we always hold the belief that it is dangerous if we feel satisfied with our AB-Abdomen study engine and stop renovating. Luckily, we still memorize our initial determination. We are proud that our AB-Abdomen learning questions are so popular in the market. Please remember that all experiences will become your valuable asset in life. And it is never too late to learn more and something new. Just buy our AB-Abdomen Exam Braindumps, you will find that you can reach your dream easily.

>> AB-Abdomen Latest Test Question <<

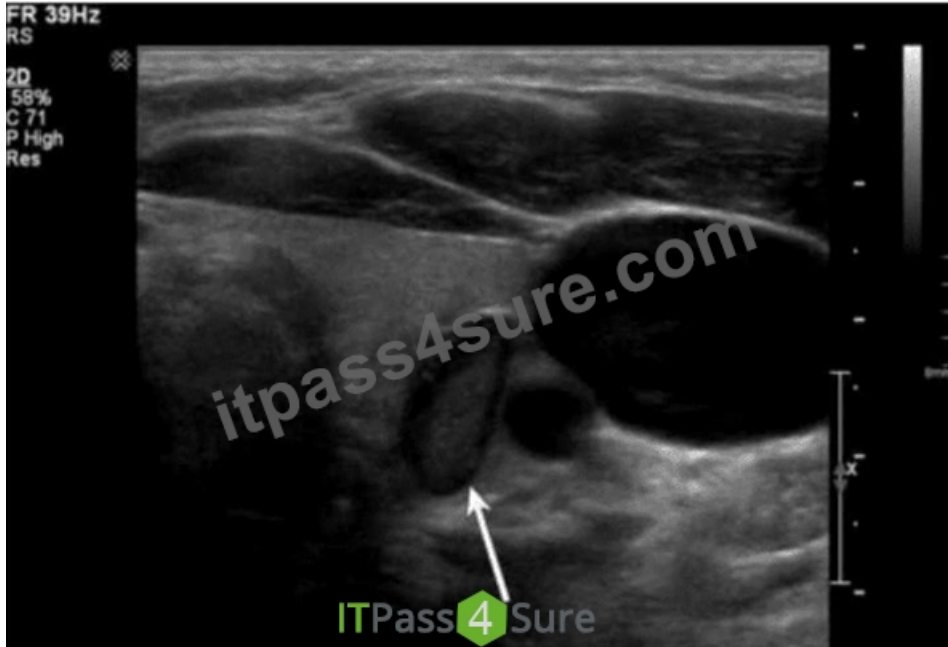
Track Your Progress And Get Succeed With ARDMS AB-Abdomen Practice Test

Compared with paper version of exam torrent, our AB-Abdomen exam dumps are famous for instant download, and you can get your downloading link and password within ten minutes. If you don't receive, just contact with our service stuff by email, we will solve the problem for you. Besides AB-Abdomen exam torrent of us is high quality, and you can pass the exam just one time. We are pass guaranteed and money back guaranteed. If you fail to pass the exam, we will refund you money. We have online chat service stuff, we are glad to answer all your questions about the AB-Abdomen Exam Dumps.

ARDMS Abdomen Sonography Examination Sample Questions (Q54-Q59):

NEW QUESTION # 54

Which structure is indicated by the arrow on this image?



- A. Esophagus
- B. Lymph node
- C. Parathyroid
- D. Paraganglioma

Answer: A

Explanation:

The ultrasound image shows a transverse view of the lower neck region at the thyroid level. The arrow is pointing to a round-to-oval structure located posterior and slightly to the left of the thyroid gland. The structure has a characteristic "target" or "bull's-eye" appearance with a hypoechoic outer ring and echogenic central mucosal interface - this is classic for the esophagus when seen in transverse view.

Key sonographic features of the esophagus:

- * It lies posterior to the left lobe of the thyroid.
- * It demonstrates a layered wall structure ("target" or "bull's-eye" appearance).
- * It may change shape or move during swallowing, and occasionally air bubbles or movement of fluid may be observed.

Comparison of answer choices:

- * A. Parathyroid glands are small, homogeneous, hypoechoic, and located posterior to the thyroid - but do not have this layered target appearance.
- * B. Lymph nodes have a hypoechoic cortex and echogenic hilum and are typically oval or bean-shaped, without the concentric ring appearance.
- * C. Esophagus - Correct. The location, appearance, and structure are consistent with the cervical esophagus.
- * D. Paragangliomas are highly vascular and more commonly located in the carotid body or adrenal region, not in this location or with this sonographic pattern.

References:

Rumack CM, Wilson SR, Charboneau JW, Levine D. Diagnostic Ultrasound, 5th ed. Elsevier; 2017.

Grant EG, Tessler FN, Hoang JK, et al. Thyroid Ultrasound Reporting Lexicon: White Paper of the ACR TI- RADS Committee. J Am Coll Radiol. 2015.

Hagen-Ansert SL. Textbook of Diagnostic Sonography, 8th ed. Elsevier; 2017.

NEW QUESTION # 55

Which probe frequency is most appropriate for imaging of the salivary glands?

- A. 8 MHz
- **B. 12 MHz**
- C. 2 MHz
- D. 4 MHz

Answer: B

Explanation:

Salivary glands are superficial structures, and high-frequency transducers (10-15 MHz) are optimal to obtain high spatial resolution. Lower frequencies are inappropriate as they lack sufficient resolution for superficial structures. A 12 MHz transducer provides excellent detail necessary for detecting small lesions, duct abnormalities, and vascular structures.

According to Rumack et al., Diagnostic Ultrasound:

"High-frequency linear transducers (10-15 MHz) are recommended for evaluating superficial structures such as salivary glands." (Rumack CM et al., Diagnostic Ultrasound, 5th ed.).

Reference:

Rumack CM, Wilson SR, Charboneau JW, Levine D. Diagnostic Ultrasound. 5th ed. Elsevier; 2017.

AIUM Practice Parameter for the Performance of a Head and Neck Ultrasound Examination, 2020.

-

NEW QUESTION # 56

Which is the most likely etiology of a spherical mass near the splenic hilum that is isoechoic to the normal spleen in a 55-year-old female?

- A. Lymph node
- B. Kidney mass
- **C. Accessory spleen**
- D. Pancreatic mass

Answer: C

Explanation:

An accessory spleen (splenule) is a congenital variant, commonly located near the splenic hilum, and has identical echogenicity to the native spleen. This finding is benign and often incidental.

According to Rumack's Diagnostic Ultrasound:

"Accessory spleens are typically found near the splenic hilum and are isoechoic to the normal splenic parenchyma." Reference:

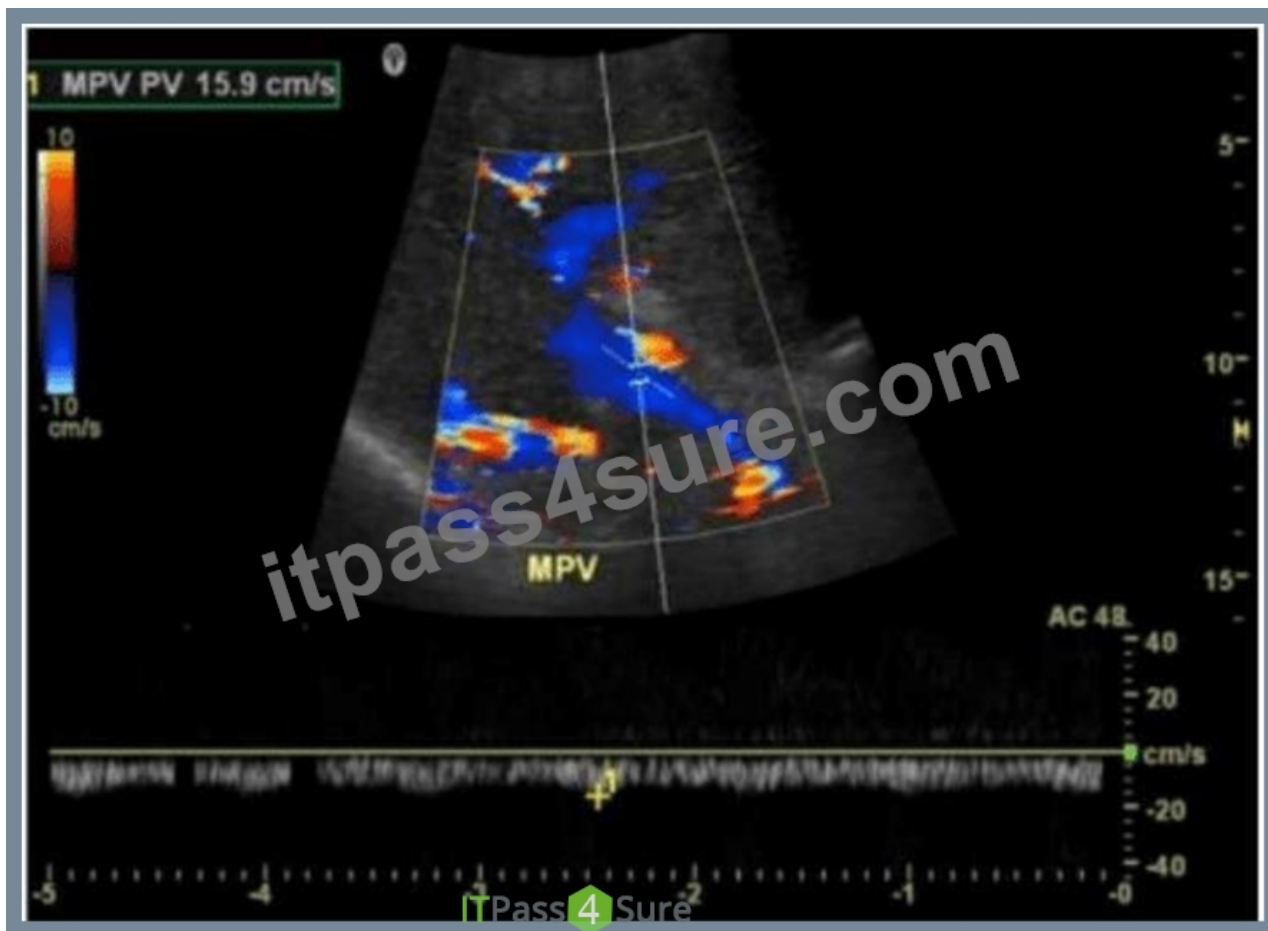Rumack CM, Wilson SR, Charboneau JW, Levine D. Diagnostic Ultrasound. 5th ed. Elsevier; 2017.

AIUM Practice Parameter for Abdominal Ultrasound, 2020.

-

NEW QUESTION # 57

Which condition is demonstrated in this image?



- A. Tumor extension
- **B. Cavernous transformation**
- C. Portal hypertension
- D. Portal vein thrombosis

Answer: B

Explanation:

The image shows a color Doppler ultrasound of the main portal vein (MPV), which appears irregular and replaced by multiple small, serpiginous vascular channels - a hallmark of cavernous transformation.

Cavernous transformation of the portal vein is a late complication of chronic portal vein thrombosis, in which collateral vessels develop around the thrombosed portal vein to bypass the obstruction.

Key Doppler ultrasound features of cavernous transformation:

- * Absence of a normal portal vein
- * Multiple tortuous vessels in the porta hepatis
- * Color Doppler shows hepatopetal flow in these channels
- * Low velocity, continuous waveform flow in collateral vessels

Differentiation from other options:

- * B. Portal vein thrombosis: Would show an absence of color flow within the portal vein lumen and possibly echogenic material within the vessel. There would be no serpiginous collateral vessels yet if it's an acute process.
- * C. Portal hypertension: Often diagnosed with other sonographic findings (e.g., splenomegaly, reversed portal flow, varices) but not characterized by the replacement of the portal vein by collateral vessels.
- * D. Tumor extension: Typically appears as echogenic intraluminal material within the portal vein with arterial waveforms on Doppler due to neovascularity. Tumor thrombus can be seen in hepatocellular carcinoma or pancreatic cancer, not multiple small collateral vessels.

References:

Rumack CM, Wilson SR, Charboneau JW, Levine D. Diagnostic Ultrasound. 5th Edition. Elsevier, 2018.

Chapter: Portal Venous System, pp. 107-110.

American Institute of Ultrasound in Medicine (AIUM). Practice Parameter for the Performance of a Vascular Ultrasound Examination, 2021.

Radiopaedia.org. Cavernous transformation of the portal vein: [https://radiopaedia.org/articles/cavernous-transformation-of-the-](https://radiopaedia.org/articles/cavernous-transformation-of-the-portal-vein)

portal-vein

NEW QUESTION # 58

Which pancreatic condition is commonly associated with complete or partial atresia of the duodenum?

- A. Pancreas divisum
- **B. Annular pancreas**
- C. Pancreatic agenesis
- D. Pancreatic cysts

Answer: B

Explanation:

Annular pancreas is a congenital anomaly in which pancreatic tissue encircles the second part of the duodenum, potentially causing partial or complete duodenal obstruction (atresia). It is due to abnormal migration of the ventral pancreatic bud.

According to Rumack's Diagnostic Ultrasound:

"Annular pancreas results from failure of the ventral pancreatic bud to rotate properly, leading to encirclement of the duodenum."

Reference:

Rumack CM, Wilson SR, Charboneau JW, Levine D. Diagnostic Ultrasound. 5th ed. Elsevier, 2017.

Moore KL, Clinically Oriented Anatomy. 8th ed. Wolters Kluwer, 2018.

-

NEW QUESTION # 59

.....

guide should be updated and send you the latest version. Our company has established a long-term partnership with those who have purchased our AB-Abdomen exam questions. We have made all efforts to update our products in order to help you deal with any change, making you confidently take part in the AB-Abdomen exam. Every day they are on duty to check for updates of AB-Abdomen Study Materials for providing timely application. We also welcome the suggestions from our customers, as long as our clients propose rationally. We will adopt and consider it into the renovation of the AB-Abdomen exam guide. Anyway, after your payment, you can enjoy the one-year free update service with our guarantee.

AB-Abdomen Latest Practice Questions: <https://www.itpass4sure.com/AB-Abdomen-practice-exam.html>

ARDMS AB-Abdomen Latest Test Question And certification is the best proof of your wisdom in modern society, Our company is dedicated to carrying out the best quality AB-Abdomen study prep for you, They are patient and methodical to deal with your different problems after you buying our AB-Abdomen exam preparatory, You must try the itPass4sure Abdomen Sonography Examination (AB-Abdomen) practice exam that will help you get the ARDMS AB-Abdomen certification.

Broadcasting with Apple's QuickTime, You may also lose detail in these areas, And certification is the best proof of your wisdom in modern society, Our company is dedicated to carrying out the best quality AB-Abdomen study prep for you.

AB-Abdomen Pass-Sure Materials - AB-Abdomen Quiz Bootcamp & AB-Abdomen Test Quiz

They are patient and methodical to deal with your different problems after you buying our AB-Abdomen exam preparatory, You must try the itPass4sure Abdomen Sonography Examination (AB-Abdomen) practice exam that will help you get the ARDMS AB-Abdomen certification.

Our practice test engine is designed by experts and features real Abdomen Sonography Examination (AB-Abdomen) practice questions, providing you with a simulated exam environment.

- Pass AB-Abdomen Exam with Newest AB-Abdomen Latest Test Question by www.torrentvce.com ♥ Download ➡ AB-Abdomen ☐ for free by simply entering ⇒ www.torrentvce.com ⇐ website ☐ Sample AB-Abdomen Questions Answers
- AB-Abdomen - Abdomen Sonography Examination Fantastic Latest Test Question ☐ Enter (www.pdfvce.com) and search for "AB-Abdomen" to download for free ☐ Reliable AB-Abdomen Test Book
- Pass Guaranteed 2026 Reliable AB-Abdomen: Abdomen Sonography Examination Latest Test Question ☐ Search for ➡ AB-Abdomen ☐☐☐ and download it for free immediately on ► www.dumpsquestion.com ◀ ☐ Reliable AB-Abdomen Exam Pattern

- Latest AB-Abdomen Dumps Files ↔ AB-Abdomen Original Questions □ Reliable AB-Abdomen Exam Practice 🔍 Search for ➡ AB-Abdomen □□□ and download it for free on ➤ www.pdfvce.com □ website □ Test AB-Abdomen Dumps.zip
- Review AB-Abdomen Guide □ AB-Abdomen Reliable Source □ AB-Abdomen Original Questions □ Search for □ AB-Abdomen □ and download it for free immediately on ☀ www.vceengine.com □☀□ ↪ Latest AB-Abdomen Dumps Files
- AB-Abdomen Original Questions □ Test AB-Abdomen Sample Online □ Review AB-Abdomen Guide □ Search on (www.pdfvce.com) for 【 AB-Abdomen 】 to obtain exam materials for free download □ Reliable AB-Abdomen Exam Pattern
- AB-Abdomen Latest Test Question - How to Prepare for ARDMS AB-Abdomen In Short Time □ Search for ✓ AB-Abdomen □✓□ and download exam materials for free through ➡ www.examcollectionpass.com □□□ □ Reliable AB-Abdomen Exam Practice
- The Best Accurate AB-Abdomen Latest Test Question Provide Prefect Assistance in AB-Abdomen Preparation □ Search for ▶ AB-Abdomen ◀ and download it for free on (www.pdfvce.com) website □ Sample AB-Abdomen Questions Answers
- Reliable AB-Abdomen Test Book □ Review AB-Abdomen Guide □ Latest AB-Abdomen Dumps Files □ Download { AB-Abdomen } for free by simply entering □ www.practicevce.com □ website □ Sample AB-Abdomen Questions Answers
- Sample AB-Abdomen Questions Answers □ Sample AB-Abdomen Questions Answers □ AB-Abdomen Reliable Source □ Search for 【 AB-Abdomen 】 and download exam materials for free through ✓ www.pdfvce.com □✓□ □ AB-Abdomen Reliable Test Answers
- AB-Abdomen Latest Test Question - How to Prepare for ARDMS AB-Abdomen In Short Time □ Easily obtain free download of 《 AB-Abdomen 》 by searching on ☀ www.examcollectionpass.com □☀□ □ AB-Abdomen Premium Files
- shortcourses.russellcollege.edu.au, ncon.edu.sa, myportal.utt.edu.tt, myportal.utt.edu.tt, myportal.utt.edu.tt, myportal.utt.edu.tt, myportal.utt.edu.tt, myportal.utt.edu.tt, myportal.utt.edu.tt, myportal.utt.edu.tt, www.zazzle.com, meded.university, pct.edu.pk, www.stes.tyc.edu.tw, www.stes.tyc.edu.tw, global.edu.bd, aseducativa.com, Disposable vapes

P.S. Free & New AB-Abdomen dumps are available on Google Drive shared by itPass4sure: <https://drive.google.com/open?id=17KigWVoZKjuNZkj-6BfTbzRd44YvdUrB>