

AE-Adult-Echocardiography Deutsche - AE-Adult-Echocardiography Lerntipps

Revised AE Adult Echocardiography Course

Please Get the Link of the Exam to proceed further - <https://www.educationry.com/?product=pass-ae-adult-echocardiography-certification-exam-educationry>

Are you preparing for the exam? Do you have the plan to study for the exam? Are you going to follow the current syllabus? If so, you are not on track. There are many questions that you should be asking yourself before starting your preparation. The first question should be: What do I want to achieve in this exam? Will this help me get a job or will it just give me another qualification? You should also think about the time and money that you are willing to spend on achieving this goal. If it is important, then why not use some of these resources wisely? You can get access to study material by subscribing to our website and taking advantage of our free practice tests. Before proceeding, one should also see all the essential features offered by us to get the right dumps material and that benefit as well. It includes two very easy format, one is the dumps and the other is the online practice test engine. Both have its importance.

One should have the actual questions and answers that help to get through the exam. For the comfort of the candidate, real questions and answers are provided so that one can easily learn the exam. The practice questions can be easily accessible and one can easily go through such material easily. The best part about the dumps is that one can download it easily anywhere like on a PC, laptop, or even on a smartphone device from where one can even prepare for an Exam when they are outside and away from home. To clear the Exam, one should learn the dumps but it is also very important to enhance confidence and skills. For this purpose one should use the online practice test engine in order to get success. This helps the candidate to get through the exam easily. There is learning mode as well as test mode both of which will help at the same time.

Experts had made the right dumps for the candidate in order to get success in the Exam. One can easily work hard by learning from these dumps and this won't waste time as well. The best thing is that these exam dumps help to clear all the concepts that help the candidate proceed and clear the Exam in no time. Often the syllabus of the Exam gets updated. Because of which the candidate might get in trouble. But we take the responsibility to provide with all the recent information and exam syllabus changes to those who had purchased the dumps for three months. This latest updates will help the candidate to prepare Exam as per the requirement. And with this update one can easily learn the exam.

Außerdem sind jetzt einige Teile dieser Pass4Test AE-Adult-Echocardiography Prüfungsfragen kostenlos erhältlich:
<https://drive.google.com/open?id=1DS5ytxcB9e0PoPejOiepq-wsJYyiGNae>

Pass4Test ist eine gute Website, die effiziente Ausbildung zur ARDMS AE-Adult-Echocardiography Zertifizierungsprüfung bietet. Und Pass4Test verspricht, dass Sie die ARDMS AE-Adult-Echocardiography Zertifizierungsprüfung bestehen können. Sonst geben wir Ihnen eine volle Rückerstattung. Vorm Kauf unserer Produkte können Sie im Internet teilweise die Demo zur ARDMS AE-Adult-Echocardiography Zertifizierungsprüfung von Pass4Test kostenlos herunterladen. Dann werden Sie mehr Vertrauen in unsere Produkte setzen. Sie können sich dann gut auf Ihre ARDMS AE-Adult-Echocardiography Zertifizierungsprüfung vorbereiten.

Pass4Test ist eine Website, die Bedürfnisse der Kunden abdecken kann. Diejenigen, die unsere Simulationssoftware zur ARDMS AE-Adult-Echocardiography IT-Zertifizierungsprüfung benutzt und die Prüfung bestanden haben, sind unsere Stammgäste geworden. Pass4Test stellt Ihnen die fortschrittliche Ausbildungstechnik zur Verfügung, die Ihnen beim Bestehen der ARDMS AE-Adult-Echocardiography Zertifizierungsprüfung hilft.

>> AE-Adult-Echocardiography Deutsche <<

AE-Adult-Echocardiography Lerntipps & AE-Adult-Echocardiography Dumps

Wir Pass4Test sind die professionellen Anbieter der Schulungsunterlagen zur ARDMS AE-Adult-Echocardiography Zertifizierungsprüfung. Seit langem betrachten wir Pass4Test das Angebot der besten Prüfungsunterlagen zur ARDMS AE-Adult-Echocardiography Zertifizierungsprüfung als unser Ziel. Verglichen zu anderen Webseiten, wir Pass4Test sind immer von anderen

vertraut. Warum? Weil wir Pass4Test vieljährige Erfahrungen haben, aufmerksam auf die IT-Zertifizierung-Studie machen und viele Prüfungsregeln sammeln. Damit können wir Pass4Test sehr hohe Hit-Rate haben. Das gewährleistet die Durchlauftrate.

ARDMS AE-Adult-Echocardiography Prüfungsplan:

Thema	Einzelheiten
Thema 1	<ul style="list-style-type: none"> Instrumentation, Optimization, and Contrast: This section of the exam measures skills of adult echocardiography technicians related to use and optimization of ultrasound instrumentation and the application of contrast agents. Candidates should recognize imaging artifacts, utilize non-imaging transducers, and adjust ultrasound console settings for optimal imaging and Doppler recordings. Knowledge of harmonic imaging, principles of contrast agents, and the safe and effective use of saline and echo-enhancing contrast agents is essential. Candidates must also be able to optimize images when using contrast agents to ensure diagnostic quality.
Thema 2	<ul style="list-style-type: none"> Anatomy and Physiology: This section of the exam measures skills of adult echocardiography technicians and covers knowledge and abilities related to normal cardiac anatomy and physiology. It includes assessing great vessels like the aorta and pulmonary arteries, recognizing anatomic variants of the heart, and evaluating cardiac chambers, pericardium, valve structures, and vessels of arterial and venous return. Candidates must document normal systolic and diastolic function, normal valve function and measurements, the phases of the cardiac cycle, normal Doppler changes with respiration, and appearance of arterial and venous waveforms. This also involves assessing the normal hemodynamic response to stress testing and maneuvers such as Valsalva, respiratory, handgrip, and postural changes.
Thema 3	<ul style="list-style-type: none"> Clinical Care and Safety: This section of the exam measures skills of adult echocardiography technicians in applying clinical care principles and safety protocols. It includes evaluating patient history and external data, preparing patients including fasting state and intravenous line management, proper patient positioning, EKG lead placement, blood pressure measurement, and ergonomic techniques. Candidates are expected to identify critical echocardiographic findings, know contraindications for procedures, and be able to respond and manage medical emergencies that may arise during echocardiographic exams.
Thema 4	<ul style="list-style-type: none"> Pathology: This section of the exam measures skills of adult echocardiography technicians and focuses on identifying and evaluating abnormal physiology and perfusion and postoperative conditions. It includes assessment of ventricular aneurysms, aortic and valve abnormalities, arrhythmias, cardiac masses, diastolic dysfunction, endocarditis, ischemic diseases, cardiomyopathies, congenital anomalies, and postoperative valve repair or replacement and intracardiac devices. Candidates must demonstrate ability to recognize abnormal Doppler signals, EKG changes, wall motion abnormalities, and a wide range of cardiac pathologies including pulmonary hypertension and septal defects.
Thema 5	<ul style="list-style-type: none"> Measurement Techniques, Maneuvers, and Sonographic Views: This section of the exam measures skills of adult echocardiography technicians in performing accurate cardiac measurements, conducting provocative maneuvers, and obtaining optimized sonographic imaging views. It involves applying 2D, 3D, M-mode, and Doppler techniques to measure heart valves, chambers, and vessels, including the aortic valve, mitral valve, left and right ventricles, atria, pulmonary artery, and shunt ratios. Candidates must instruct patients in maneuvers such as Valsalva, cough, sniff, and squat. They should also be proficient in acquiring standard echocardiographic views including apical, parasternal, subcostal, and suprasternal notch views.

ARDMS AE Adult Echocardiography Examination AE-Adult-Echocardiography Prüfungsfragen mit Lösungen (Q29-Q34):

29. Frage

What is a normal response to dobutamine stress testing?

- A. An increase in left ventricular cavity size and a decrease in systolic blood pressure
- B. A decrease in left ventricular cavity size and a decrease in systolic blood pressure
- C. An increase in left ventricular cavity size and an increase in systolic blood pressure
- **D. A decrease in left ventricular cavity size and an increase in systolic blood pressure**

Antwort: D

Begründung:

During dobutamine stress testing, a normal physiological response includes increased myocardial contractility leading to a decrease in left ventricular (LV) cavity size during systole due to more effective ejection.

Concurrently, systolic blood pressure increases due to the inotropic and chronotropic effects of dobutamine.

An increase in LV cavity size during stress would suggest impaired contractility or ischemia, which is abnormal.

This normal response is detailed in the "Textbook of Clinical Echocardiography, 6e", Chapter on Stress Echocardiography and Hemodynamic Responses#20:400-405Textbook of Clinical Echocardiography#.

30. Frage

Which finding is most consistent with this M-mode image?

- A. Rheumatic mitral stenosis
- B. Mitral valve annuloplasty ring
- C. Systolic anterior motion of the mitral valve
- D. Mitral valve prolapse

Antwort: A

Begründung:

Comprehensive and Detailed Explanation From Exact Extract:

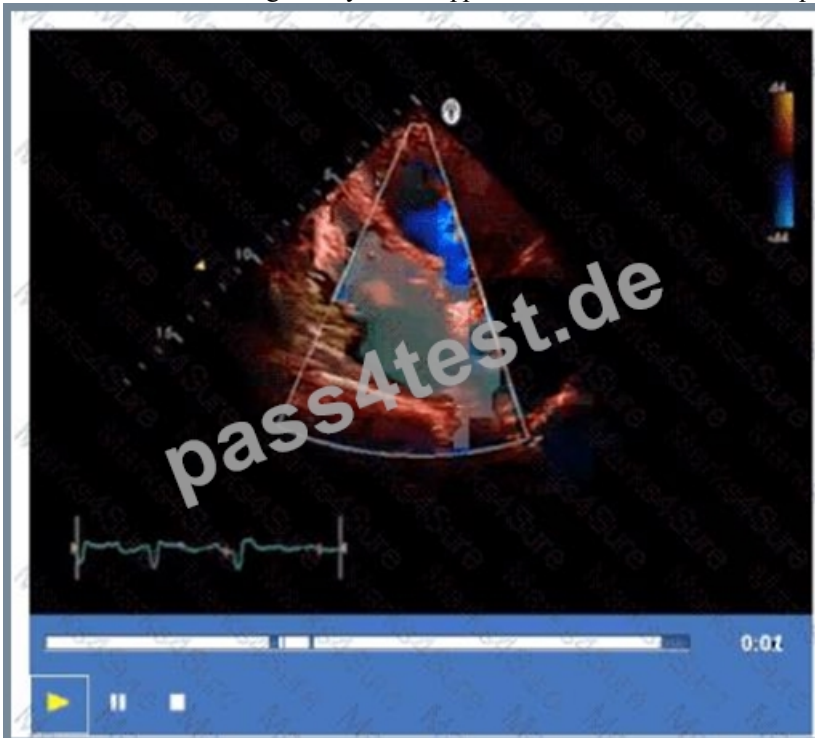
This M-mode echocardiographic image shows thickened mitral valve leaflets with a characteristic "doming" or "hockey-stick" appearance during diastole, which is classic for rheumatic mitral stenosis. Rheumatic mitral stenosis leads to leaflet thickening, restricted opening, and calcification, which alters the normal mitral valve motion on M-mode.

Mitral valve prolapse would show systolic displacement of the leaflets into the left atrium, typically later in systole, not doming in diastole. Mitral valve annuloplasty ring would appear as a bright echogenic line around the annulus but is not seen in this image. Systolic anterior motion (SAM) of the mitral valve is usually seen in hypertrophic cardiomyopathy and presents as anterior motion during systole, not the diastolic pattern shown.

This classical M-mode appearance is described in "Textbook of Clinical Echocardiography, 6e", Chapter on Rheumatic Valve Disease#20:385-390Textbook of Clinical Echocardiography#.

31. Frage

What is the incidental finding seen by color Doppler in this four-chamber view of a patient with left atrial enlargement?



- A. Sinus venosus defect
- B. Coronary-cameral fistula

- C. Patent foramen ovale
- D. Muscular ventricular septal defect

Antwort: C

Begründung:

The color Doppler image in the four-chamber view shows a jet across the interatrial septum, indicating a shunt at the atrial level. In a patient with left atrial enlargement, the most common incidental finding causing such flow is a patent foramen ovale (PFO). A PFO is a small communication between the right and left atria that can open under certain pressure conditions, leading to shunting.

Muscular ventricular septal defect is a ventricular level defect and would be seen in different views. Coronary- cameral fistula is a rare anomaly involving abnormal connections between coronary arteries and cardiac chambers, not typical in this setting. Sinus venosus defect is an atypical atrial septal defect located near the superior vena cava and would require different imaging planes for detection.

This finding and its implications are discussed in the "Textbook of Clinical Echocardiography, 6e", Chapter on Atrial Septal Defects and Shunts#20:115-120Textbook of Clinical Echocardiography#.

32. Frage

A patient presents with tender, red lesions on their fingers and toes (Osler nodes). Which finding is most likely?

- A. Lambl excrescences
- B. Carcinoid heart disease
- C. Papillary fibroelastoma
- D. Infective endocarditis

Antwort: D

Begründung:

Osler nodes are tender, erythematous nodules typically located on the fingers and toes, and are a classic sign of infective endocarditis (IE). They represent immune complex deposition and microemboli causing localized vasculitis.

Carcinoid heart disease presents with right-sided valve fibrosis and not with Osler nodes. Lambl excrescences are small filiform valvular strands without clinical manifestations such as Osler nodes. Papillary fibroelastomas are benign cardiac tumors that may cause emboli but not immune-mediated skin lesions.

This classic clinical sign and its echocardiographic correlation in IE are discussed in the "Textbook of Clinical Echocardiography, 6e", Chapter on Infective Endocarditis#20:400-405Textbook of Clinical Echocardiography#.

33. Frage

A "dropout" or loss of echoes from structures posterior to a calcified mitral annulus results in which artifact?

- A. Shadowing
- B. Side lobe
- C. Ring-down
- D. Reverberation

Antwort: A

Begründung:

Acoustic shadowing is the artifact caused by calcified structures like the mitral annulus, resulting in attenuation or loss of echoes from structures posterior to the calcification. The calcification absorbs or reflects the ultrasound waves, preventing them from reaching deeper structures and causing a "dropout" or dark shadow behind the calcified area.

Reverberation involves repeated reflections creating multiple echoes. Side lobe artifacts arise from off-axis beams. Ring-down artifacts result from resonance in fluid or gas bubbles, not calcifications.

This artifact is explained in the "Textbook of Clinical Echocardiography, 6e", Chapter on Ultrasound Artifacts #20:75-80Textbook of Clinical Echocardiography#.

34. Frage

.....

Pass4Test ist eine Website, die die Erfolgsquote von ARDMS AE-Adult-Echocardiography Zertifizierungsprüfung erhöhen kann.

Die erfahrungsreichen IT-Experten entwickeln ständig eine Vielzahl von Programmen, um zu garantieren, dass Sie die ARDMS AE-Adult-Echocardiography Zertifizierungsprüfung 100% erfolgreich bestehen können. Die Trainingsmaterialien von Pass4Test sind sehr effektiv. Viele IT-Leute, die die ARDMS AE-Adult-Echocardiography Prüfung bestanden haben, haben die Prüfungsfragen und Antworten von Pass4Test benutzt. Mit Hilfe des Pass4Test haben viele auch die ARDMS AE-Adult-Echocardiography Zertifizierungsprüfung bestanden. Wenn Sie Pass4Test wählen, kommt der Erfolg auf Sie zu.

AE-Adult-Echocardiography Lerntipps: <https://www.pass4test.de/AE-Adult-Echocardiography.html>

- AE-Adult-Echocardiography Unterlagen mit echte Prüfungsfragen der ARDMS Zertifizierung Öffnen Sie die Webseite ➔ www.zertpruefung.ch und suchen Sie nach kostenloser Download von **【 AE-Adult-Echocardiography 】** AE-Adult-Echocardiography PDF Testsoftware
- AE-Adult-Echocardiography AE Adult Echocardiography Examination neueste Studie Torrent - AE-Adult-Echocardiography tatsächliche prep Prüfung Geben Sie www.itzert.com ein und suchen Sie nach kostenloser Download von [AE-Adult-Echocardiography] AE-Adult-Echocardiography Fragen Antworten
- AE-Adult-Echocardiography AE Adult Echocardiography Examination neueste Studie Torrent - AE-Adult-Echocardiography tatsächliche prep Prüfung Suchen Sie auf der Webseite de.fast2test.com nach AE-Adult-Echocardiography und laden Sie es kostenlos herunter AE-Adult-Echocardiography Prüfungen
- AE Adult Echocardiography Examination cexamkiller Praxis Dumps - AE-Adult-Echocardiography Test Training Überprüfungen Geben Sie **【 www.itzert.com 】** ein und suchen Sie nach kostenloser Download von ➔ AE-Adult-Echocardiography AE-Adult-Echocardiography Prüfungsunterlagen
- AE-Adult-Echocardiography Prüfungsvorbereitung AE-Adult-Echocardiography Fragen Beantworten AE-Adult-Echocardiography Online Prüfung Suchen Sie auf der Webseite www.it-pruefung.com nach “ AE-Adult-Echocardiography ” und laden Sie es kostenlos herunter AE-Adult-Echocardiography Fragen Beantworten
- AE-Adult-Echocardiography PDF Testsoftware AE-Adult-Echocardiography Buch AE-Adult-Echocardiography Prüfungen Suchen Sie auf ➔ www.itzert.com nach kostenlosem Download von (AE-Adult-Echocardiography) AE-Adult-Echocardiography Praxisprüfung
- AE-Adult-Echocardiography Unterlagen mit echte Prüfungsfragen der ARDMS Zertifizierung Öffnen Sie die Webseite www.pass4test.de und suchen Sie nach kostenloser Download von AE-Adult-Echocardiography AE-Adult-Echocardiography Fragen Antworten
- AE-Adult-Echocardiography Test Dumps, AE-Adult-Echocardiography VCE Engine Ausbildung, AE-Adult-Echocardiography aktuelle Prüfung Geben Sie (www.itzert.com) ein und suchen Sie nach kostenloser Download von ➔ AE-Adult-Echocardiography AE-Adult-Echocardiography Deutsch Prüfung
- AE-Adult-Echocardiography Online Prüfung AE-Adult-Echocardiography Deutsch Prüfung AE-Adult-Echocardiography Testfragen Suchen Sie jetzt auf ➔ www.pass4test.de nach { AE-Adult-Echocardiography } und laden Sie es kostenlos herunter AE-Adult-Echocardiography Praxisprüfung
- Kostenlose gültige Prüfung ARDMS AE-Adult-Echocardiography Sammlung - Examcollection Öffnen Sie die Webseite www.itzert.com und suchen Sie nach kostenloser Download von ➔ AE-Adult-Echocardiography AE-Adult-Echocardiography Fragen Antworten
- AE-Adult-Echocardiography Fragen Antworten AE-Adult-Echocardiography Testfragen AE-Adult-Echocardiography Fragen Antworten Suchen Sie jetzt auf“ www.pruefungfrage.de ” nach ➔ AE-Adult-Echocardiography und laden Sie es kostenlos herunter AE-Adult-Echocardiography Fragen Beantworten
- madbookmarks.com, monobookmarks.com, macieicxw064638.blogdems.com, deannauhvb906830.lotlegendswiki.com, tamzintqab610078.laowablog.com, nicolecxay011098.bloggerchest.com, majaqxhp889081.theisblog.com, jadackgu434089.dgbloggers.com, allyourbookmarks.com, hannazhup611021.blogpayz.com, Disposable vapes

BONUS!!! Laden Sie die vollständige Version der Pass4Test AE-Adult-Echocardiography Prüfungsfragen kostenlos herunter:
<https://drive.google.com/open?id=1DS5ytxcB9e0PoPejOiepq-wsJYyGNae>