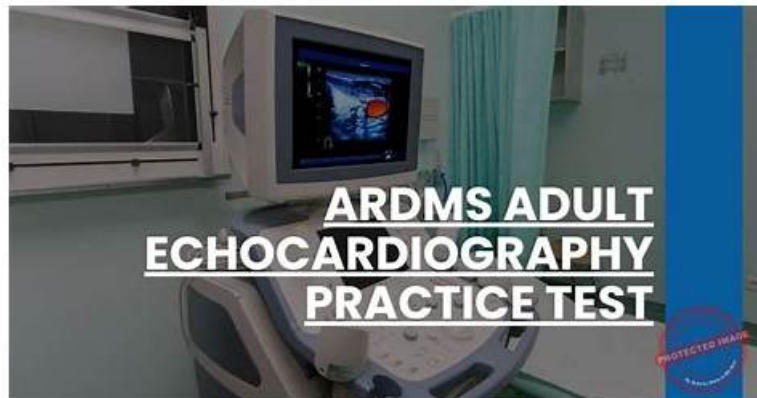


ARDMS AE-Adult-Echocardiography Practice Test - 100% Exam Passing Guarantee (2026)



What's more, part of that ExamDiscuss AE-Adult-Echocardiography dumps now are free: <https://drive.google.com/open?id=1w2ktJyN4dQvTgBaoH8dImyxCS3P08nU->

AE Adult Echocardiography Examination AE-Adult-Echocardiography practice test software always keeps track of previous AE-Adult-Echocardiography practice exam attempts and shows the changes and improvements in every attempt. All the AE Adult Echocardiography Examination questions given in AE Adult Echocardiography Examination pdf questions file and practice test software are very similar to the actual AE Adult Echocardiography Examination AE-Adult-Echocardiography Exam Questions. So it eliminates the hassle of AE-Adult-Echocardiography exam fear. The desktop AE-Adult-Echocardiography practice exam software is compatible with windows based computers. There are many customers support team of ExamDiscuss always to fix any problems.

The most important thing for preparing the AE-Adult-Echocardiography exam is reviewing the essential point. Some students learn all the knowledge of the test. They still fail because they just remember the less important point. In order to service the candidates better, we have issued the AE-Adult-Echocardiography test engine for you. Our company has accumulated so much experience about the test. So we can predict the real test precisely. Almost half questions and answers of the real exam occur on our AE-Adult-Echocardiography practice material. That means if you study our study guide, your passing rate is much higher than other candidates. Preparing the AE-Adult-Echocardiography exam has shortcut. From now, stop learning by yourself and try our test engine. All your efforts will pay off one day.

>> AE-Adult-Echocardiography Latest Study Guide <<

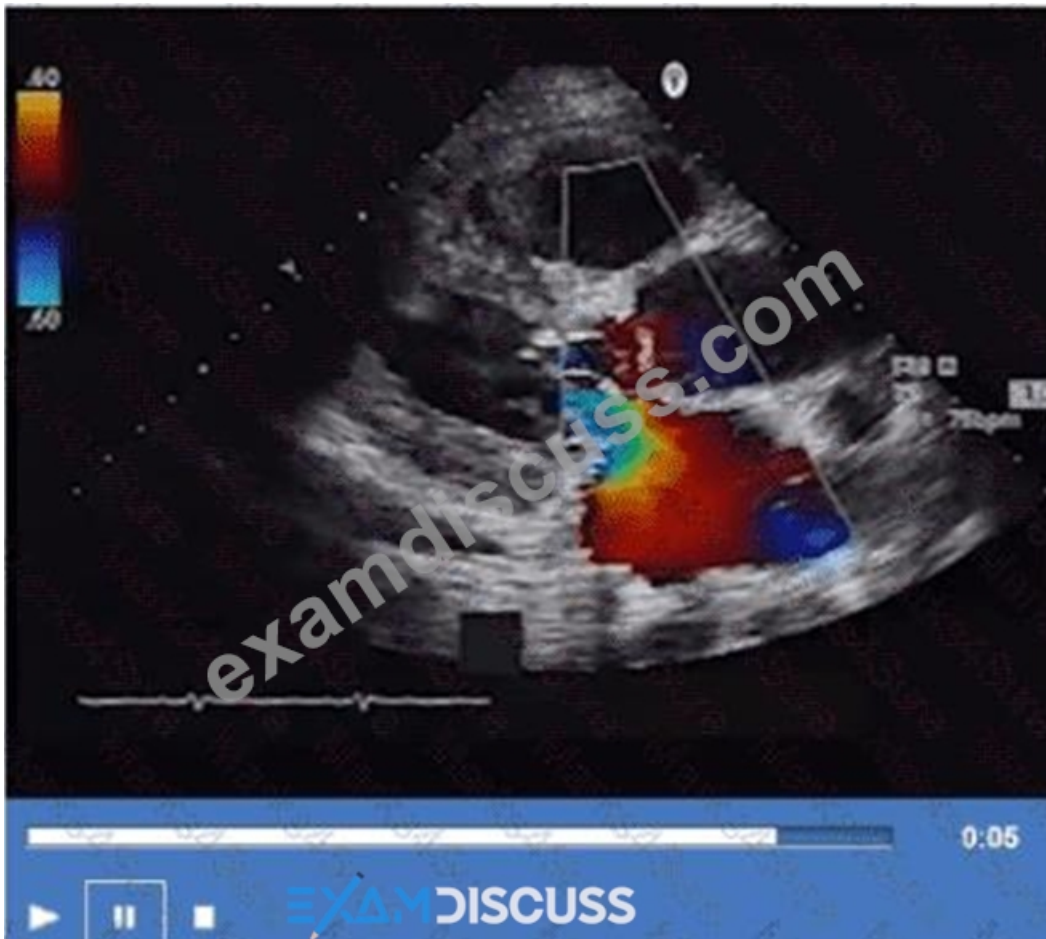
AE-Adult-Echocardiography Study Dumps | AE-Adult-Echocardiography Exam Sims

Our company employs a professional service team which traces and records the popular trend among the industry and the latest update of the knowledge about the AE-Adult-Echocardiography exam reference. We give priority to keeping pace with the times and providing the advanced views to the clients. We keep a close watch at the most advanced social views about the knowledge of the test AE-Adult-Echocardiography Certification. Our experts will renovate the test bank with the latest AE-Adult-Echocardiography exam practice question and compile the latest knowledge and information into the questions and answers.

ARDMS AE Adult Echocardiography Examination Sample Questions (Q110-Q115):

NEW QUESTION # 110

What is the direction of the mitral regurgitant jet in this video clip?



- A. Posterior
- B. Medial
- C. Anterior
- D. Lateral

Answer: A

Explanation:

The color Doppler jet in the apical four-chamber view is directed posteriorly toward the posterior left atrial wall, indicating a posteriorly directed mitral regurgitant jet.

Jet direction can provide insight into the mechanism of mitral regurgitation; for example, anterior leaflet prolapse often causes a posteriorly directed jet.

This analysis is outlined in the "Textbook of Clinical Echocardiography, 6e", Chapter on Mitral Regurgitation

- Jet Direction and Mechanism#20:390-395Textbook of Clinical Echocardiography#.

NEW QUESTION # 111

The 'P' wave of an electrocardiogram relates to which echocardiography event?

- A. Ventricular contraction
- B. Ventricular diastole
- C. Atrial relaxation
- D. Atrial contraction

Answer: D

Explanation:

Comprehensive and Detailed Explanation From Exact Extract:

The P wave on the ECG corresponds to atrial depolarization, which precedes atrial contraction (atrial systole).

On echocardiography, atrial contraction can be observed as the atrial "kick," contributing to ventricular filling during late diastole.

Ventricular contraction (QRS complex) and ventricular relaxation (T wave) correspond to other phases of the cardiac cycle. Atrial

relaxation occurs during ventricular systole but is not represented by the P wave.

This timing relationship is critical for correlating echocardiographic Doppler inflow patterns, such as the late diastolic A wave, with the ECG. These concepts are outlined in the foundational echocardiography references, including ASE guidelines and the "Textbook of Clinical Echocardiography" 16:Textbook of Clinical Echocardiography, 6e. 150-155 12:ASE Echocardiography Guidelines. 50-55.

NEW QUESTION # 112

Sinus of Valsalva aneurysms most commonly rupture into which structure(s)?

- A. Left atrium
- **B. Right heart chambers**
- C. Coronary sinus
- D. Pericardial space

Answer: B

Explanation:

Sinus of Valsalva aneurysms typically rupture into the right heart chambers, most commonly the right atrium or right ventricle. This creates a left-to-right shunt and can lead to volume overload and heart failure if not treated.

Rupture into the pericardial space is less common and may cause tamponade. Rupture into the left atrium or coronary sinus is rare. This clinical detail is described in the "Textbook of Clinical Echocardiography, 6e", Chapter on Aortic Root Pathology and Sinus of Valsalva Aneurysms 20:420-425 Textbook of Clinical Echocardiography.

NEW QUESTION # 113

Which finding is most consistent with this M-mode image?

- A. Mitral valve prolapse
- B. Systolic anterior motion of the mitral valve
- C. Mitral valve annuloplasty ring
- **D. Rheumatic mitral stenosis**

Answer: D

Explanation:

Comprehensive and Detailed Explanation From Exact Extract:

This M-mode echocardiographic image shows thickened mitral valve leaflets with a characteristic "doming" or "hockey-stick" appearance during diastole, which is classic for rheumatic mitral stenosis. Rheumatic mitral stenosis leads to leaflet thickening, restricted opening, and calcification, which alters the normal mitral valve motion on M-mode.

Mitral valve prolapse would show systolic displacement of the leaflets into the left atrium, typically later in systole, not doming in diastole. Mitral valve annuloplasty ring would appear as a bright echogenic line around the annulus but is not seen in this image. Systolic anterior motion (SAM) of the mitral valve is usually seen in hypertrophic cardiomyopathy and presents as anterior motion during systole, not the diastolic pattern shown.

This classical M-mode appearance is described in "Textbook of Clinical Echocardiography, 6e", Chapter on Rheumatic Valve Disease 20:385-390 Textbook of Clinical Echocardiography.

NEW QUESTION # 114

Which hepatic vein flow pattern signals severe tricuspid regurgitation?

- A. Biphasic flow reversal in diastole
- **B. Flow reversal in systole**
- C. Flow reversal in diastole
- D. Atrial flow reversal in systole

Answer: B

Explanation:

In severe tricuspid regurgitation (TR), the regurgitant jet flows back from the right ventricle into the right atrium during systole, causing reversal of flow in the hepatic veins during the same phase. On Doppler echocardiography, this manifests as systolic flow

reversal in the hepatic veins, which is a hallmark sign of severe TR.

Normally, hepatic vein flow consists of a predominant systolic forward flow into the right atrium. However, in severe TR, the high pressure in the right atrium during systole causes retrograde flow in the hepatic veins.

This pattern is diagnostic and aids in severity assessment.

Diastolic flow reversal is uncommon in TR and more associated with other pathologies. Atrial flow reversal in systole or biphasic flow reversal in diastole are not recognized patterns for severe TR.

This is described in detail in the "Textbook of Clinical Echocardiography, 6e", Chapter on Right Heart and Tricuspid Valve Disease, with Doppler patterns illustrated for hepatic vein flow in tricuspid regurgitation#20:

330-335Textbook of Clinical Echocardiography#.

NEW QUESTION # 115

.....

AE-Adult-Echocardiography practice materials stand the test of time and harsh market, convey their sense of proficiency with passing rate up to 98 to 100 percent. They are 100 percent guaranteed AE-Adult-Echocardiography learning quiz. And our content of the AE-Adult-Echocardiography Exam Questions are based on real exam by whittling down superfluous knowledge without delinquent mistakes. At the same time, we always keep updating the AE-Adult-Echocardiography training guide to the most accurate and the latest.

AE-Adult-Echocardiography Study Dumps: <https://www.examdumps.com/ARDMS/exam/AE-Adult-Echocardiography/>

ARDMS AE-Adult-Echocardiography Latest Study Guide Whether you prefer web-based practice exam, desktop-based exam, or PDF real questions, we've got you covered, Passing the AE-Adult-Echocardiography Study Dumps AE-Adult-Echocardiography Study Dumps - AE Adult Echocardiography Examination exam is not only for obtaining a paper certification, but also for a proof of your ability, 99% passing rate.

Important aspects are things like pins, voltages, cable specification, AE-Adult-Echocardiography network adapters, etc, This is one of the most recent books written on the topic of automated software testing.

Whether you prefer web-based practice exam, desktop-based exam, or PDF real questions, AE-Adult-Echocardiography Exam Sims we've got you covered, Passing the ARDMS RDCS AE Adult Echocardiography Examination exam is not only for obtaining a paper certification, but also for a proof of your ability.

2026 Efficient AE-Adult-Echocardiography Latest Study Guide | AE Adult Echocardiography Examination 100% Free Study Dumps

99% passing rate, If you worry that you will not get the satisfied results after you have taken too much time and energy to prepare ARDMS AE-Adult-Echocardiography Actual Test.

In order to meet the demand of our customers better, we will compile the newest resources through a variety of ways and update our AE-Adult-Echocardiography exam braindumps: AE Adult Echocardiography Examination some time, then our operation system will automatically send the downloading link of the latest and the most useful AE-Adult-Echocardiography study guide to your e-mail within the whole year after purchase.

- Pass AE-Adult-Echocardiography Exam ☐ Valid AE-Adult-Echocardiography Real Test ☐ AE-Adult-Echocardiography Certification Exam * Download 「 AE-Adult-Echocardiography 」 for free by simply searching on (www.prepawaypdf.com) ☐ Valid AE-Adult-Echocardiography Test Vce
- Pass Guaranteed 2026 First-grade ARDMS AE-Adult-Echocardiography: AE Adult Echocardiography Examination Latest Study Guide ☐ Go to website ➡ www.pdfvce.com ☐ ☐ open and search for (AE-Adult-Echocardiography) to download for free ☐ Valid AE-Adult-Echocardiography Test Vce
- Use ARDMS AE-Adult-Echocardiography Practice Exam Software (Desktop and Web-Based) For Self Evaluation ☐ Search for ▶ AE-Adult-Echocardiography ◀ on ☐ www.practicevce.com ☐ immediately to obtain a free download ☺Reliable AE-Adult-Echocardiography Exam Questions
- Perfect AE-Adult-Echocardiography Latest Study Guide - Win Your ARDMS Certificate with Top Score ☐ The page for free download of[AE-Adult-Echocardiography] on ☐ www.pdfvce.com ☐ will open immediately ☐ AE-Adult-Echocardiography Reliable Braindumps Files
- Exam AE-Adult-Echocardiography Tutorials ☐ AE-Adult-Echocardiography Exam Dumps Demo ☐ Reliable AE-Adult-Echocardiography Exam Guide ➡ Simply search for 「 AE-Adult-Echocardiography 」 for free download on ☐ www.troytecdumps.com ☐ ☐ Exam Vce AE-Adult-Echocardiography Free
- Pass Guaranteed 2026 First-grade ARDMS AE-Adult-Echocardiography: AE Adult Echocardiography Examination Latest

- Perfect AE-Adult-Echocardiography Latest Study Guide - Win Your ARDMS Certificate with Top Score ☐ Enter { www.examcollectionpass.com } and search for “AE-Adult-Echocardiography” to download for free ☐ AE-Adult-Echocardiography Exam Dumps Demo

- DOWNLOAD the newest ExamDiscuss AE-Adult-Echocardiography PDF dumps from Cloud Storage for free:
<https://drive.google.com/open?id=1w2ktJyN4dQvTgBaoH8dImyxCS3P08nU->

DOWNLOAD the newest ExamDiscuss AE-Adult-Echocardiography PDF dumps from Cloud Storage for free:
<https://drive.google.com/open?id=1w2ktJyN4dQvTgBaoH8dImyxCS3P08nU->