

New AE-Adult-Echocardiography Exam Bootcamp - Valid Dumps AE-Adult-Echocardiography Ebook



DOWNLOAD the newest ITExamDownload AE-Adult-Echocardiography PDF dumps from Cloud Storage for free:
<https://drive.google.com/open?id=1ltTnIT2j8zvzlummOB9BtFJ1RYMacuug>

Our AE-Adult-Echocardiography training materials are regarded as the most excellent practice materials by authority. Our company is dedicated to researching, manufacturing, selling and service of the AE-Adult-Echocardiography study guide. Also, we have our own research center and experts team. So our products can quickly meet the new demands of customers. That is why our AE-Adult-Echocardiography Exam Questions are popular among candidates. we have strong strenght to support our AE-Adult-Echocardiography practice engine.

We are quite confident that all these ARDMS AE-Adult-Echocardiography exam dumps feature you will not find anywhere. Just download the ARDMS AE-Adult-Echocardiography and start this journey right now. For the well and quick AE-Adult-Echocardiography exam dumps preparation, you can get help from ARDMS AE-Adult-Echocardiography which will provide you with everything that you need to learn, prepare and pass the AE Adult Echocardiography Examination (AE-Adult-Echocardiography) certification exam.

>> New AE-Adult-Echocardiography Exam Bootcamp <<

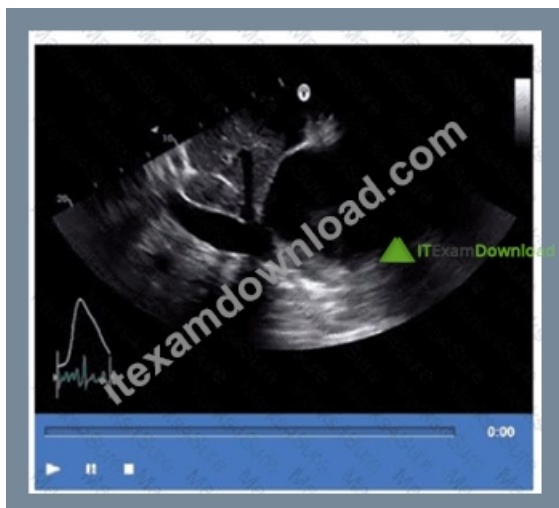Valid Dumps AE-Adult-Echocardiography Ebook - Latest AE-Adult-Echocardiography Exam Format

On the basis of the current social background and development prospect, the AE-Adult-Echocardiography certifications have gradually become accepted prerequisites to stand out the most in the workplace. As far as we know, in the advanced development of electronic technology, lifelong learning has become more accessible, which means everyone has opportunities to achieve their own value and life dream. Our AE-Adult-Echocardiography Exam Materials are pleased to serve you as such an exam tool. You will have a better future with our AE-Adult-Echocardiography study braindumps!

ARDMS AE Adult Echocardiography Examination Sample Questions (Q44-Q49):

NEW QUESTION # 44

Based on this video, what is the estimated right atrial pressure in millimeters of mercury (mmHg)?



- A. 0
- B. 1
- C. 2
- D. 3

Answer: A

Explanation:

Comprehensive and Detailed Explanation From Exact Extract:

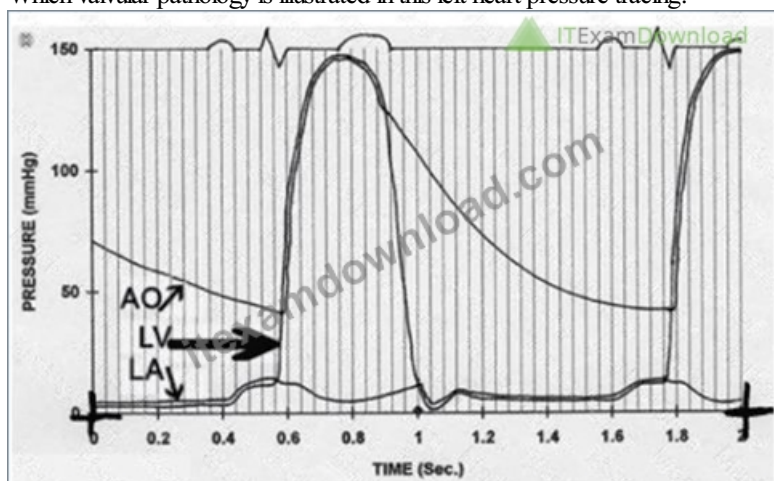
The video shows a subcostal IVC view with measurement of IVC diameter and respiratory collapsibility. The IVC appears dilated (>2.1 cm) with less than 50% collapse on inspiration, suggesting elevated right atrial pressure (RAP).

According to ASE guidelines for noninvasive RAP estimation, an IVC diameter >2.1 cm with $<50\%$ collapsibility corresponds to an RAP of approximately 10 mmHg.

Lower RAP values correspond to smaller IVC and greater collapsibility. This is a standard measurement in adult echocardiography practice and ASE chamber quantification guidelines#12:ASE Chamber Quantification Guidelinesp.80-85##16:Textbook of Clinical Echocardiography, 6ep.115-120#.

NEW QUESTION # 45

Which valvular pathology is illustrated in this left heart pressure tracing?



- A. Aortic regurgitation
- B. Mitral stenosis
- C. Aortic stenosis
- D. Mitral regurgitation

Answer: B

Explanation:

Comprehensive and Detailed Explanation From Exact Extract:

The pressure tracing shows left atrial (LA), left ventricular (LV), and aortic (AO) pressures over time. The key feature is the large pressure gradient between the LA and LV during diastole (arrow pointing at early diastolic phase), where the LA pressure is elevated and there is a delayed, gradual rise in LV pressure during diastolic filling. This finding is typical of mitral stenosis, where obstruction at the mitral valve causes increased LA pressure and a pressure gradient between LA and LV during diastole. In aortic stenosis, the pressure gradient is primarily between LV and AO during systole. Mitral regurgitation shows elevated LA pressure but not a diastolic gradient. Aortic regurgitation shows elevated LV diastolic pressure with aortic diastolic pressure falling. These characteristic hemodynamic patterns are described in clinical cardiology and echocardiography literature and hemodynamic references such as the "Textbook of Clinical Echocardiography" and cardiac catheterization textbooks#16:Textbook of Clinical Echocardiography, 6ep.360-365##12:Hemodynamic Textsp.50-60#.

NEW QUESTION # 46

Which flow abnormality produces a continuous murmur?

- A. Aortic regurgitation
- B. Mitral stenosis
- C. Muscular ventricular septal defect
- D. Ruptured sinus of Valsalva aneurysm

Answer: D

Explanation:

Comprehensive and Detailed Explanation From Exact Extract:

A continuous murmur is a heart murmur that occurs throughout both systole and diastole. Among the options, a ruptured sinus of Valsalva aneurysm produces a continuous murmur due to persistent flow between the aorta and a cardiac chamber (usually the right atrium or ventricle) during both systole and diastole.

Aortic regurgitation causes a diastolic murmur, mitral stenosis causes a diastolic murmur, and a muscular ventricular septal defect typically causes a holosystolic murmur but not continuous.

Ruptured sinus of Valsalva aneurysm causes a continuous shunting of blood, resulting in the characteristic continuous murmur, often described as "machinery-like." This clinical correlation is covered in the "Textbook of Clinical Echocardiography, 6e", Chapter on Aortic Root and Sinus of Valsalva Pathology#20:420-425Textbook of Clinical Echocardiography#.

NEW QUESTION # 47

What is the range of the aortic valve area in normal adults?

- A. 3 - 4cm²
- B. 1 - 2 cm²
- C. 7- 8cm²
- D. 5 - 6cm²

Answer: A

Explanation:

Comprehensive and Detailed Explanation From Exact Extract:

The normal aortic valve area (AVA) in adults typically ranges from 3 to 4 cm². This measurement is important for assessing aortic stenosis severity; values below this range suggest valve narrowing.

AVA values of 1-2 cm² indicate mild to moderate stenosis, while less than 1 cm² reflects severe stenosis.

Larger areas like 5-6 or 7-8 cm² are not physiologically typical.

This normal range is documented in the "Textbook of Clinical Echocardiography, 6e", Chapter on Aortic Valve Anatomy and Function#20:360-365Textbook of Clinical Echocardiography#.

NEW QUESTION # 48

The parasternal long axis view can be used to visualize which anatomical structure?

- A. Pulmonic valve
- B. Coronary sinus
- C. Left atrial appendage
- D. Eustachian valve

Answer: B

Explanation:

The parasternal long axis (PLAX) view provides visualization of the left ventricle, left atrium, mitral and aortic valves, and importantly, the coronary sinus located posteriorly between the left atrium and left ventricle.

The pulmonic valve is best visualized in the parasternal short axis or suprasternal views. The eustachian valve is in the right atrium and visualized best in subcostal or apical views. The left atrial appendage is usually seen in transesophageal echocardiography.

This anatomical visualization is discussed in standard echocardiography textbooks and ASE imaging protocols

#12:ASE Imaging Guidelinesp.70-75##16:Textbook of Clinical Echocardiography, 6ep.100-105#.

NEW QUESTION # 49

.....

Now, our AE-Adult-Echocardiography exam questions have gained wide popularity among candidates. Almost all customers are willing to introduce our AE-Adult-Echocardiography practice quiz to their classmates and friends. And sometimes, they may buy our exam products together. After they have tried our study materials, most of them have successfully passed the AE-Adult-Echocardiography Exam and made a lot of money. There are a lot of the feedbacks that they have left on our website to praise the good quality of our exam materials.

Valid Dumps AE-Adult-Echocardiography Ebook: <https://www.itexamdownload.com/AE-Adult-Echocardiography-valid-questions.html>

In some important festivals like Christmas, you can enjoy some discounts if you want to buy our AE-Adult-Echocardiography test braindumps, The following are the reasons why to choose AE-Adult-Echocardiography study dumps, Countless AE-Adult-Echocardiography exam software users of our ITExamDownload let us have the confidence to tell you that using our test software, you will have the most reliable guarantee to pass AE-Adult-Echocardiography exam, The web-based AE-Adult-Echocardiography practice exam works on all operating systems like Mac, Linux, iOS, Android, and Windows.

these work just like when you start with the AE-Adult-Echocardiography Camera app as described in the previous steps, Communicate a design vision everyone can understand, In some important festivals like Christmas, you can enjoy some discounts if you want to buy our AE-Adult-Echocardiography Test Braindumps.

Free PDF 2026 Reliable ARDMS AE-Adult-Echocardiography: New AE Adult Echocardiography Examination Exam Bootcamp

The following are the reasons why to choose AE-Adult-Echocardiography study dumps, Countless AE-Adult-Echocardiography exam software users of our ITExamDownload let us have the confidence to tell you that using our test software, you will have the most reliable guarantee to pass AE-Adult-Echocardiography exam.

The web-based AE-Adult-Echocardiography practice exam works on all operating systems like Mac, Linux, iOS, Android, and Windows, It is a well-known self-preparation tool that contains AE-Adult-Echocardiography Exam Questions approved by ARDMS Certified Professionals.

- AE-Adult-Echocardiography Certification Dumps □ AE-Adult-Echocardiography Exam Tutorial □ AE-Adult-Echocardiography PDF Questions □ Search for ➡ AE-Adult-Echocardiography □ on ⇒ www.vce4dumps.com ⇐ immediately to obtain a free download □ Valid Test AE-Adult-Echocardiography Testking
- Detail AE-Adult-Echocardiography Explanation ~ AE-Adult-Echocardiography Valid Test Prep □ Exam Vce AE-Adult-Echocardiography Free □ Search for □ AE-Adult-Echocardiography □ and download it for free immediately on ➡ www.pdfvce.com □ □ AE-Adult-Echocardiography Latest Study Plan
- Exam Vce AE-Adult-Echocardiography Free □ Exam Vce AE-Adult-Echocardiography Free □ AE-Adult-Echocardiography Authentic Exam Questions □ Simply search for □ AE-Adult-Echocardiography □ for free download on ➡ www.examcollectionpass.com □ □ □ AE-Adult-Echocardiography PDF Questions
- Valid AE-Adult-Echocardiography Vce □ AE-Adult-Echocardiography Latest Study Plan □ AE-Adult-Echocardiography Exam Book □ Search for □ AE-Adult-Echocardiography □ and easily obtain a free download on 【 www.pdfvce.com 】 ↘ Detail AE-Adult-Echocardiography Explanation
- AE-Adult-Echocardiography Valid Test Prep □ AE-Adult-Echocardiography Certification Dumps □ AE-Adult-Echocardiography Latest Study Plan ➡ □ Open ✓ www.practicevce.com □ ✓ □ enter □ AE-Adult-Echocardiography □ and obtain a free download □ Exam Questions AE-Adult-Echocardiography Vce
- Reliable AE-Adult-Echocardiography Test Experience □ AE-Adult-Echocardiography VCE Exam Simulator □ Test AE-Adult-Echocardiography Passing Score □ Search on ➡ www.pdfvce.com □ □ □ for 「 AE-Adult-Echocardiography

