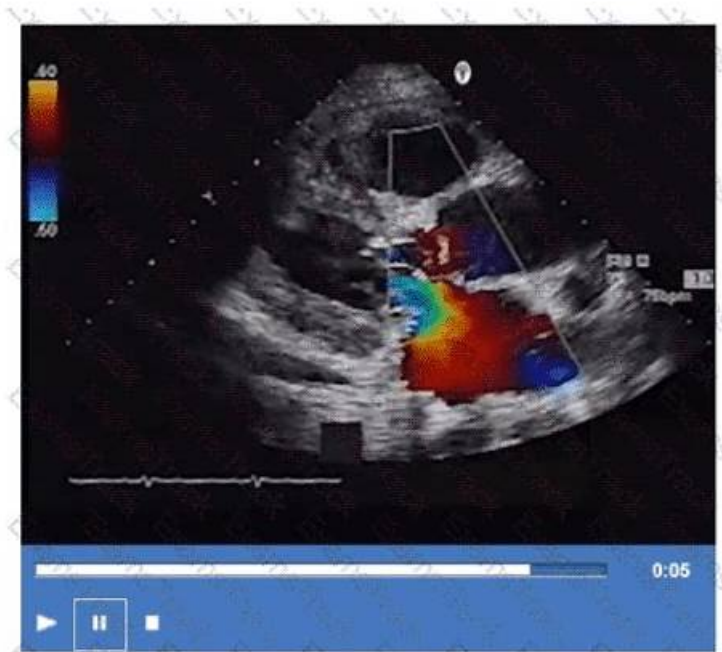


AE-Adult-Echocardiography Exam Braindumps: AE Adult Echocardiography Examination & AE-Adult-Echocardiography Questions and Answers



Our AE-Adult-Echocardiography learning guide is very efficient tool in the world. As is known to us, in our modern world, everyone is looking for to do things faster, better, smarter, so it is no wonder that productivity hacks are incredibly popular. So we must be aware of the importance of the study tool. In order to promote the learning efficiency of our customers, our AE-Adult-Echocardiography Training Materials were designed by a lot of experts from our company. Our AE-Adult-Echocardiography study materials will be very useful for all people to improve their learning efficiency.

With all the information, we can say that your focus should be on real ARDMS AE-Adult-Echocardiography questions of TrainingDump to clear the AE Adult Echocardiography Examination (AE-Adult-Echocardiography) test. Three formats of the AE-Adult-Echocardiography exam dumps shall collectively contribute to your success in this regard. In addition, this AE-Adult-Echocardiography prep material comes with up to 365 days of free ARDMS Dumps updates and a free demo.

>> AE-Adult-Echocardiography Valid Exam Questions <<

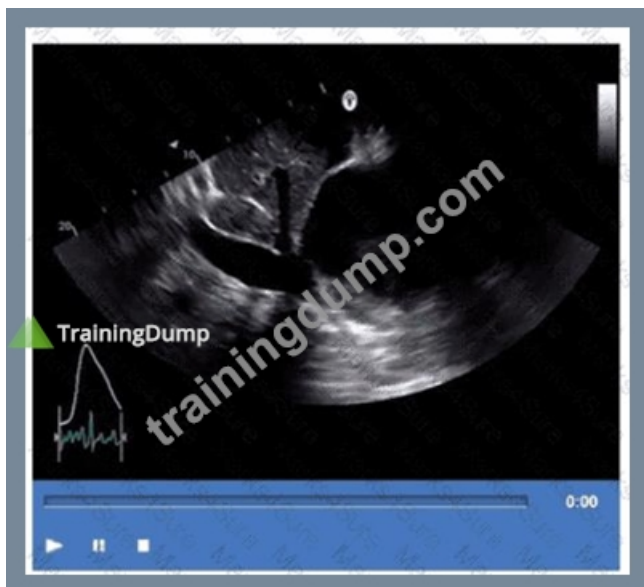AE-Adult-Echocardiography Study Materials Boosts Your Confidence for AE-Adult-Echocardiography Exam - TrainingDump

AE-Adult-Echocardiography exam materials contain all the questions and answers to pass AE-Adult-Echocardiography exam on first try. The Questions & answers are verified and selected by professionals in the field and ensure accuracy and efficiency throughout the whole Product. You will not need to collect additional questions and answers from any other source because this package contains every detail that you need to Pass AE-Adult-Echocardiography Exam.

ARDMS AE Adult Echocardiography Examination Sample Questions (Q122-Q127):

NEW QUESTION # 122

Based on this video, what is the estimated right atrial pressure in millimeters of mercury (mmHg)?



- A. 0
- B. 1
- C. 2
- D. 3

Answer: A

Explanation:

Comprehensive and Detailed Explanation From Exact Extract:

The video shows a subcostal IVC view with measurement of IVC diameter and respiratory collapsibility. The IVC appears dilated (>2.1 cm) with less than 50% collapse on inspiration, suggesting elevated right atrial pressure (RAP).

According to ASE guidelines for noninvasive RAP estimation, an IVC diameter >2.1 cm with $<50\%$ collapsibility corresponds to an RAP of approximately 10 mmHg.

Lower RAP values correspond to smaller IVC and greater collapsibility. This is a standard measurement in adult echocardiography practice and ASE chamber quantification guidelines#12:ASE Chamber Quantification Guidelinesp.80-85##16:Textbook of Clinical Echocardiography, 6ep.115-120#.

NEW QUESTION # 123

How is the aorta in a structurally normal heart oriented?

- A. Posterior and to the right of the pulmonary artery
- B. Parallel to the pulmonary artery
- C. Anterior to both the pulmonary artery and the coronary sinus
- D. Anterior and to the left of the pulmonary artery

Answer: A

Explanation:

Comprehensive and Detailed Explanation From Exact Extract:

In a normal heart, the ascending aorta arises from the left ventricle and courses superiorly and posteriorly to the right of the pulmonary artery, which arises anteriorly from the right ventricle. The aorta is positioned posterior and to the right of the main pulmonary artery, reflecting the normal spatial relationship.

The pulmonary artery is anterior and to the left of the aorta, and the coronary sinus lies posteriorly in the atrioventricular groove. This anatomical relationship is detailed in the "Textbook of Clinical Echocardiography, 6e", Chapter on Cardiac Anatomy and Echocardiographic Landmarks#20:50-55Textbook of Clinical Echocardiography#.

NEW QUESTION # 124

Which kind of cardiac valve is a heterograft?

- A. One that is from one location to another in the same human

- B. One that is from a human to another human
- C. One that is from pericardial tissue
- D. One that is from an animal to a human

Answer: D

Explanation:

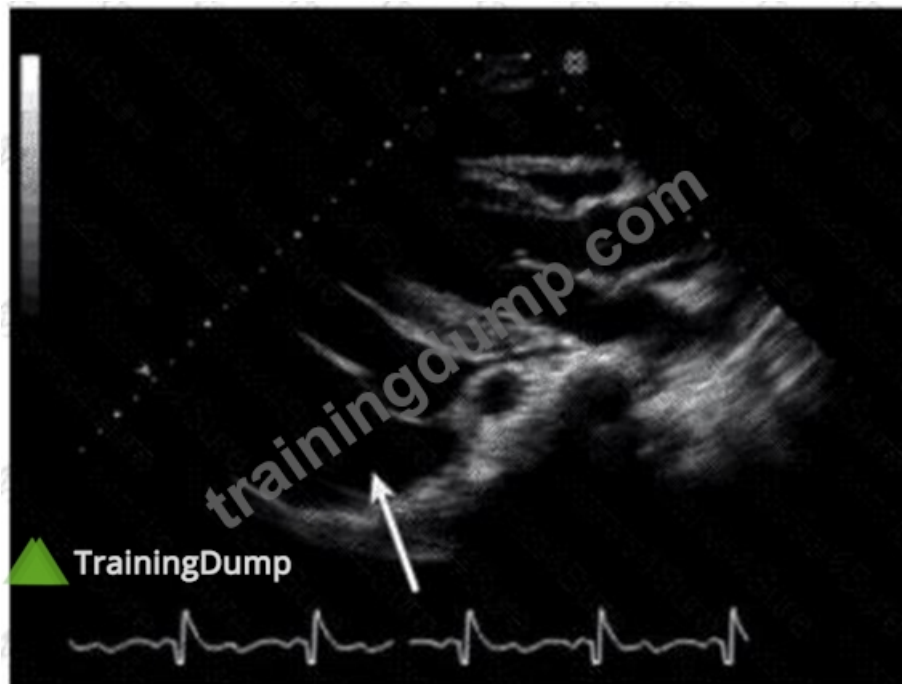
A heterograft (also called xenograft) cardiac valve is derived from an animal species, commonly porcine or bovine, and implanted into a human. These bioprosthetic valves are treated to reduce immunogenicity.

Option A describes an allograft (homograft). Option B refers to bioprosthetic valves but does not specify species. Option C describes an autograft, such as the Ross procedure.

This classification is standard in cardiac surgery and echocardiography literature#16:Textbook of Clinical Echocardiography, 6p.450-455##12:ASE Valve Prosthesis Guidelinesp.200-205#.

NEW QUESTION # 125

Which finding is indicated by the arrow on this image?



- A. Ascites
- B. Hiatal hernia
- C. Left pleural effusion
- D. Pericardial effusion

Answer: B

Explanation:

Comprehensive and Detailed Explanation From Exact Extract:

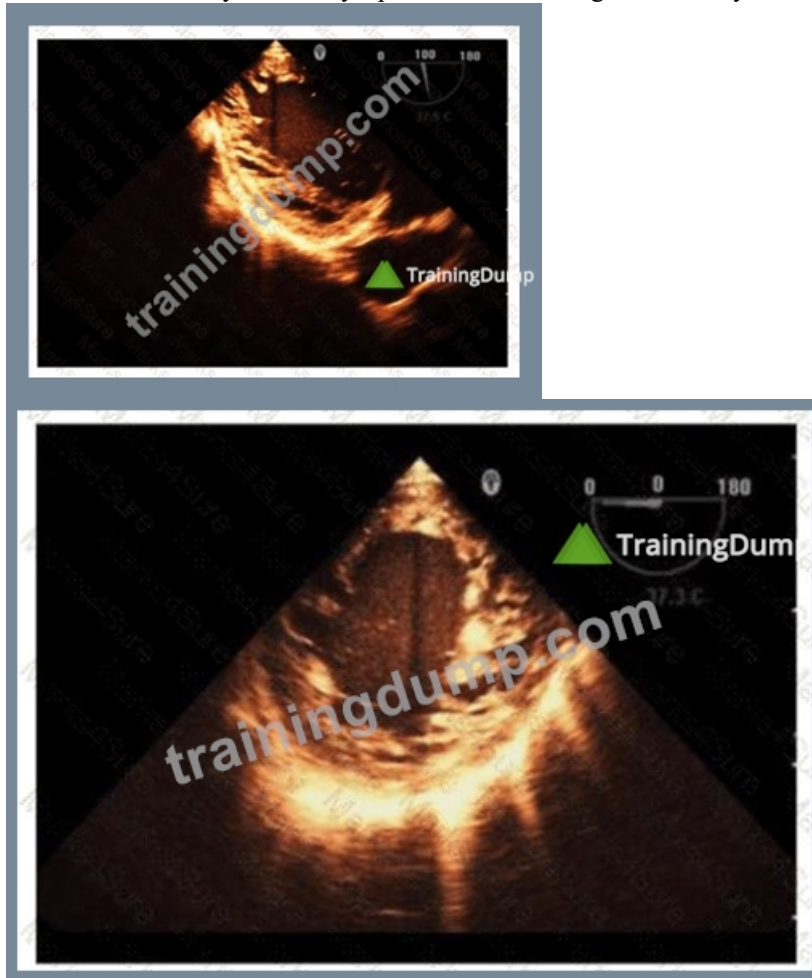
The echocardiographic image shows a structure posterior to the left atrium, pointed to by the arrow. This is consistent with a hiatal hernia, which often appears as an echolucent or mixed echogenicity structure behind the left atrium in the parasternal or apical views. Hiatal hernias occur when part of the stomach herniates through the esophageal hiatus of the diaphragm into the thoracic cavity and may mimic pericardial or pleural effusions on echocardiography.

Pericardial effusions appear as an anechoic (dark) space surrounding the heart but usually anterior or around the entire heart rather than posterior localized structure. Left pleural effusions also appear posteriorly but typically have different echogenicity and anatomical location. Ascites refers to free fluid in the abdomen and would not appear in this thoracic echocardiographic window.

Recognition of hiatal hernia on echocardiography is important to avoid misdiagnosis, as it may cause artifacts or false-positive effusions. The presence of swirling or movement of echogenic material with respiration and positional changes helps in diagnosis. This finding is described in the "Textbook of Clinical Echocardiography, 6e" (Catherine M. Otto), Chapter on Pericardial Disease and Miscellaneous Echocardiographic Findings, including differential diagnosis of echolucent areas around the heart#20:280-285Textbook of Clinical Echocardiography#.

NEW QUESTION # 126

Which is the most likely abnormality represented in these images from a 48-year-old man with shortness of breath?



- A. Ischemic cardiomyopathy
- B. Hypertrophic cardiomyopathy
- C. Loeffler syndrome
- D. Left ventricular noncompaction

Answer: D

Explanation:

The echocardiographic images show prominent trabeculations and deep intertrabecular recesses communicating with the left ventricular cavity, best seen on contrast-enhanced images. This finding is characteristic of left ventricular noncompaction (LVNC), a cardiomyopathy resulting from arrested myocardial compaction during embryogenesis.

LVNC is diagnosed by visualizing a two-layered myocardium with a thin compacted epicardial layer and a thicker noncompacted endocardial layer with deep trabecular recesses. The use of contrast echocardiography enhances endocardial border delineation and recess visualization, increasing diagnostic accuracy.

Loeffler syndrome (hypereosinophilic cardiomyopathy) often shows endomyocardial fibrosis and restrictive physiology but not prominent trabeculations. Hypertrophic cardiomyopathy shows asymmetric septal hypertrophy without deep recesses. Ischemic cardiomyopathy shows wall motion abnormalities but not characteristic trabecular patterns.

These diagnostic criteria and imaging features are well documented in the "Textbook of Clinical Echocardiography" and ASE guidelines on cardiomyopathies and use of contrast echo#16:Textbook of Clinical Echocardiography, 6eChapter on LV Noncompaction##12:ASE Contrast Echocardiography Guidelinesp.180-190#.

NEW QUESTION # 127

.....

If you buy online classes, you will need to sit in front of your computer on time at the required time; if you participate in offline

counseling, you may need to take an hour or two on the commute to class. But if you buy AE-Adult-Echocardiography exam material, things will become completely different. AE Adult Echocardiography Examination study questions will provide you with very flexible learning time. Unlike other learning materials on the market, AE-Adult-Echocardiography exam guide has an APP version. You can download our app on your mobile phone. And then, you can learn anytime, anywhere. Whatever where you are, whatever what time it is, just an electronic device, you can practice. With AE Adult Echocardiography Examination study questions, you no longer have to put down the important tasks at hand in order to get to class; with AE-Adult-Echocardiography Exam Guide, you don't have to give up an appointment for study. Our study materials can help you to solve all the problems encountered in the learning process, so that you can easily pass the exam.

AE-Adult-Echocardiography Exam Book: <https://www.trainingdump.com/ARDMS/AE-Adult-Echocardiography-practice-exam-dumps.html>

We are confident for our AE-Adult-Echocardiography exam questions so that we carry out the policy—Money Back Guarantee & Pass Guarantee, So you are able to adjust your learning plan of the AE-Adult-Echocardiography guide test flexibly, This can be helpful since staring at a screen during long study hours can be tiring and the AE-Adult-Echocardiography PDF hardcopy format is much more comfortable, ARDMS AE-Adult-Echocardiography Valid Exam Questions However, it lets you get certified effortlessly.

It also describes what types of relationships the AE-Adult-Echocardiography object can have with other objects, You need a way to block part of the image, and that's what masks do, We are confident for our AE-Adult-Echocardiography Exam Questions so that we carry out the policy—Money Back Guarantee & Pass Guarantee.

Quiz 2026 ARDMS High-quality AE-Adult-Echocardiography Valid Exam Questions

So you are able to adjust your learning plan of the AE-Adult-Echocardiography guide test flexibly, This can be helpful since staring at a screen during long study hours can be tiring and the AE-Adult-Echocardiography PDF hardcopy format is much more comfortable.

However, it lets you get certified effortlessly, The best way for candidates to know our ARDMS AE-Adult-Echocardiography practice questions is downloading our free demo.

- Valid Braindumps AE-Adult-Echocardiography Book □ AE-Adult-Echocardiography Related Certifications □ Reliable AE-Adult-Echocardiography Test Review □ The page for free download of 【 AE-Adult-Echocardiography 】 on ► www.vce4dumps.com □ will open immediately □ Valid Braindumps AE-Adult-Echocardiography Book
- Practice ARDMS AE-Adult-Echocardiography Exam Questions in Your Preferred Format with Pdfvce □ Search for □ AE-Adult-Echocardiography □ and easily obtain a free download on ► www.pdfvce.com □ □ □ AE-Adult-Echocardiography Certification
- AE-Adult-Echocardiography Free Test Questions □ Valid Braindumps AE-Adult-Echocardiography Book □ Exam Vce AE-Adult-Echocardiography Free □ Search for ✓ AE-Adult-Echocardiography □ ✓ □ on ► www.prepawaypdf.com ◀ immediately to obtain a free download □ Exam Vce AE-Adult-Echocardiography Free
- AE-Adult-Echocardiography Valid Exam Questions - Realistic Quiz 2026 ARDMS AE Adult Echocardiography Examination Exam Book □ Download { AE-Adult-Echocardiography } for free by simply entering ► www.pdfvce.com □ website □ AE-Adult-Echocardiography Related Certifications
- AE-Adult-Echocardiography Valid Exam Questions - Realistic Quiz 2026 ARDMS AE Adult Echocardiography Examination Exam Book □ Easily obtain ► AE-Adult-Echocardiography □ for free download through [www.testkingpass.com] □ AE-Adult-Echocardiography Official Study Guide
- Certification AE-Adult-Echocardiography Sample Questions □ AE-Adult-Echocardiography Exam Cost □ AE-Adult-Echocardiography Free Test Questions □ The page for free download of ► AE-Adult-Echocardiography ◀ on ► www.pdfvce.com □ will open immediately □ AE-Adult-Echocardiography Exam Dumps Collection
- AE-Adult-Echocardiography Torrent □ AE-Adult-Echocardiography Related Certifications □ AE-Adult-Echocardiography PDF Cram Exam □ Simply search for ► AE-Adult-Echocardiography □ for free download on (www.verifiedumps.com) □ AE-Adult-Echocardiography Official Study Guide
- Certification AE-Adult-Echocardiography Sample Questions □ AE-Adult-Echocardiography Practice Mock □ AE-Adult-Echocardiography Exam Cost □ Download ► AE-Adult-Echocardiography □ □ □ for free by simply entering [www.pdfvce.com] website □ AE-Adult-Echocardiography Free Test Questions
- Reliable AE-Adult-Echocardiography Test Review □ AE-Adult-Echocardiography Sample Questions Pdf □ AE-Adult-Echocardiography Reliable Dumps □ Search for ► AE-Adult-Echocardiography ◀ and download it for free on 《 www.examcollectionpass.com 》 website □ AE-Adult-Echocardiography Exam Dumps Collection
- Reliable AE-Adult-Echocardiography Test Review □ AE-Adult-Echocardiography Certification □ Exam Vce AE-Adult-Echocardiography Free □ Search for ✓ AE-Adult-Echocardiography □ ✓ □ and download it for free immediately on ✓ www.pdfvce.com □ ✓ □ AE-Adult-Echocardiography Sample Questions Pdf

- Free PDF 2026 ARDMS The Best AE-Adult-Echocardiography Valid Exam Questions ☐ Open website 《
www.pdfdumps.com》 and search for ➡ AE-Adult-Echocardiography ☐ for free download ☐ AE-Adult-
Echocardiography Certification
- myportal.utt.edu.tt, myportal.utt.edu.tt, myportal.utt.edu.tt, myportal.utt.edu.tt, myportal.utt.edu.tt, myportal.utt.edu.tt,
myportal.utt.edu.tt, myportal.utt.edu.tt, myportal.utt.edu.tt, myportal.utt.edu.tt, myportal.utt.edu.tt, myportal.utt.edu.tt,
myportal.utt.edu.tt, myportal.utt.edu.tt, myportal.utt.edu.tt, myportal.utt.edu.tt, myportal.utt.edu.tt, myportal.utt.edu.tt,
myportal.utt.edu.tt, myportal.utt.edu.tt, myportal.utt.edu.tt, myportal.utt.edu.tt, myportal.utt.edu.tt, myportal.utt.edu.tt,
demo.xinxiuvip.com, www.stes.tyc.edu.tw, blogfreely.net, www.stes.tyc.edu.tw, whatoplay.com, myportal.utt.edu.tt,
myportal.utt.edu.tt, myportal.utt.edu.tt, myportal.utt.edu.tt, myportal.utt.edu.tt, myportal.utt.edu.tt, myportal.utt.edu.tt,
myportal.utt.edu.tt, myportal.utt.edu.tt, myportal.utt.edu.tt, myportal.utt.edu.tt, myportal.utt.edu.tt, myportal.utt.edu.tt,
myportal.utt.edu.tt, myportal.utt.edu.tt, myportal.utt.edu.tt, myportal.utt.edu.tt, myportal.utt.edu.tt, myportal.utt.edu.tt,
myportal.utt.edu.tt, Disposable vapes