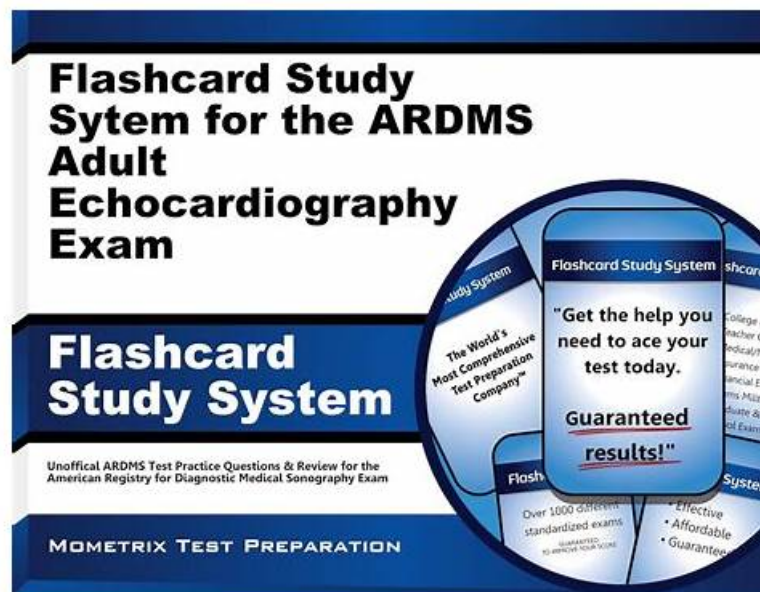


ARDMS AE-Adult-Echocardiography New Dumps Files - AE-Adult-Echocardiography New Braindumps Pdf



2025 Latest CramPDF AE-Adult-Echocardiography PDF Dumps and AE-Adult-Echocardiography Exam Engine Free Share:
<https://drive.google.com/open?id=1FCvF2hGRNqCK26AzURfewbbFP7Kxb1zF>

Nowadays everyone is interested in the field of ARDMS because it is growing rapidly day by day. The AE Adult Echocardiography Examination (AE-Adult-Echocardiography) credential is designed to validate the expertise of candidates. But most of the students are confused about the right preparation material for AE-Adult-Echocardiography Exam Dumps and they couldn't find real AE-Adult-Echocardiography exam questions so that they can pass ARDMS AE-Adult-Echocardiography certification exam in a short time with good grades.

ARDMS AE-Adult-Echocardiography Exam Syllabus Topics:

Topic	Details
Topic 1	<ul style="list-style-type: none"> Pathology: This section of the exam measures skills of adult echocardiography technicians and focuses on identifying and evaluating abnormal physiology and perfusion and postoperative conditions. It includes assessment of ventricular aneurysms, aortic and valve abnormalities, arrhythmias, cardiac masses, diastolic dysfunction, endocarditis, ischemic diseases, cardiomyopathies, congenital anomalies, and postoperative valve repair or replacement and intracardiac devices. Candidates must demonstrate ability to recognize abnormal Doppler signals, EKG changes, wall motion abnormalities, and a wide range of cardiac pathologies including pulmonary hypertension and septal defects.
Topic 2	<ul style="list-style-type: none"> Instrumentation, Optimization, and Contrast: This section of the exam measures skills of adult echocardiography technicians related to use and optimization of ultrasound instrumentation and the application of contrast agents. Candidates should recognize imaging artifacts, utilize non-imaging transducers, and adjust ultrasound console settings for optimal imaging and Doppler recordings. Knowledge of harmonic imaging, principles of contrast agents, and the safe and effective use of saline and echo-enhancing contrast agents is essential. Candidates must also be able to optimize images when using contrast agents to ensure diagnostic quality.

Topic 3	<ul style="list-style-type: none"> • Anatomy and Physiology: This section of the exam measures skills of adult echocardiography technicians and covers knowledge and abilities related to normal cardiac anatomy and physiology. It includes assessing great vessels like the aorta and pulmonary arteries, recognizing anatomic variants of the heart, and evaluating cardiac chambers, pericardium, valve structures, and vessels of arterial and venous return. Candidates must document normal systolic and diastolic function, normal valve function and measurements, the phases of the cardiac cycle, normal Doppler changes with respiration, and appearance of arterial and venous waveforms. This also involves assessing the normal hemodynamic response to stress testing and maneuvers such as Valsalva, respiratory, handgrip, and postural changes.
Topic 4	<ul style="list-style-type: none"> • Measurement Techniques, Maneuvers, and Sonographic Views: This section of the exam measures skills of adult echocardiography technicians in performing accurate cardiac measurements, conducting provocative maneuvers, and obtaining optimized sonographic imaging views. It involves applying 2D, 3D, M-mode, and Doppler techniques to measure heart valves, chambers, and vessels, including the aortic valve, mitral valve, left and right ventricles, atria, pulmonary artery, and shunt ratios. Candidates must instruct patients in maneuvers such as Valsalva, cough, sniff, and squat. They should also be proficient in acquiring standard echocardiographic views including apical, parasternal, subcostal, and suprasternal notch views.
Topic 5	<ul style="list-style-type: none"> • Clinical Care and Safety: This section of the exam measures skills of adult echocardiography technicians in applying clinical care principles and safety protocols. It includes evaluating patient history and external data, preparing patients including fasting state and intravenous line management, proper patient positioning, EKG lead placement, blood pressure measurement, and ergonomic techniques. Candidates are expected to identify critical echocardiographic findings, know contraindications for procedures, and be able to respond and manage medical emergencies that may arise during echocardiographic exams.

>> ARDMS AE-Adult-Echocardiography New Dumps Files <<

AE-Adult-Echocardiography New Brindumps Pdf & AE-Adult-Echocardiography Reliable Test Objectives

It is the time for you to earn a well-respected ARDMS certification to gain a competitive advantage in the IT job market. As we all know, it is not an easy thing to gain the AE-Adult-Echocardiography certification. What's about the AE-Adult-Echocardiography pdf dumps provided by CramPDF. Your knowledge range will be broadened and your personal skills will be enhanced by using the AE-Adult-Echocardiography free pdf torrent, then you will be brave and confident to face the AE-Adult-Echocardiography actual test.

ARDMS AE Adult Echocardiography Examination Sample Questions (Q33-Q38):

NEW QUESTION # 33

Which syndrome is associated with pulmonic stenosis?

- A. Marfan
- B. Turner
- **C. Noonan**
- D. Eisenmenger

Answer: C

Explanation:

Pulmonic stenosis is a congenital valve abnormality often seen in genetic syndromes with cardiac manifestations. Among these, Noonan syndrome is the most frequently associated with pulmonic stenosis.

Noonan syndrome is a genetic disorder characterized by distinctive facial features, short stature, and congenital heart defects, with pulmonic valve stenosis being the predominant cardiac lesion. The stenosis is usually valvular and caused by dysplastic pulmonary valve leaflets, leading to obstruction of right ventricular outflow.

Other syndromes listed do not typically present with pulmonic stenosis:

Turner syndrome is more commonly linked with bicuspid aortic valve and coarctation of the aorta, not pulmonic stenosis.

Eisenmenger syndrome refers to the advanced phase of congenital heart defects with significant pulmonary hypertension and is not a

genetic syndrome.

Marfan syndrome is predominantly associated with aortic root dilation and mitral valve prolapse, but not with pulmonic stenosis.

This association is well documented in adult echocardiography guidelines and texts, such as the "Textbook of Clinical Echocardiography" by Catherine Otto, which clearly identifies Noonan syndrome as the syndrome most commonly associated with pulmonic stenosis among congenital heart defects#16:Chapter on Congenital Heart DiseaseTextbook of Clinical Echocardiography, 6e#.

NEW QUESTION # 34

Which view is best used to evaluate a bicuspid aortic valve?

- A. Apical five-chamber
- B. Apical long axis
- C. Right sternal border
- D. Parasternal short axis

Answer: D

Explanation:

Comprehensive and Detailed Explanation From Exact Extract:

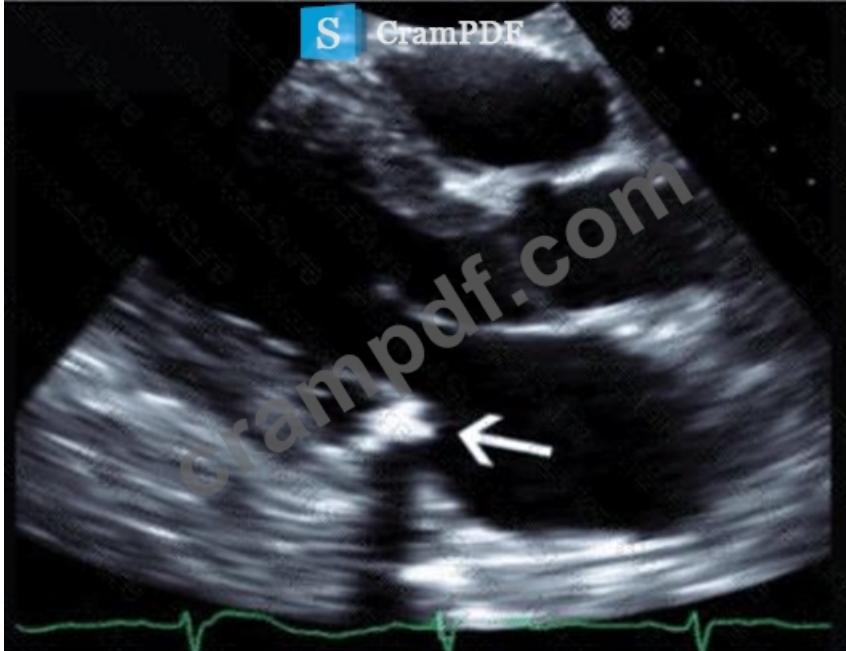The parasternal short axis view at the level of the aortic valve is optimal for evaluating valve morphology, including detection of bicuspid aortic valve (BAV). This view clearly visualizes the valve leaflets en face during systole.

Right sternal border and apical views provide hemodynamic information but are less optimal for detailed valve anatomy. Apical long axis is better for left ventricular and outflow tract evaluation but limited for valve leaflet number.

This is described in the "Textbook of Clinical Echocardiography, 6e", Chapter on Aortic Valve Morphology and Congenital Anomalies#20:350-355Textbook of Clinical Echocardiography#.

NEW QUESTION # 35

Which echogenic structure is indicated by the arrow on this image?



- A. Vegetation
- B. Annular calcification
- C. Thrombus
- D. Tumor

Answer: B

Explanation:

The image is a parasternal long-axis echocardiographic view focusing on the mitral valve annulus with a highly echogenic, dense, and

well-defined structure located at the base of the posterior mitral leaflet. This appearance is characteristic of mitral annular calcification (MAC), a degenerative process resulting in calcium deposition along the mitral valve annulus.

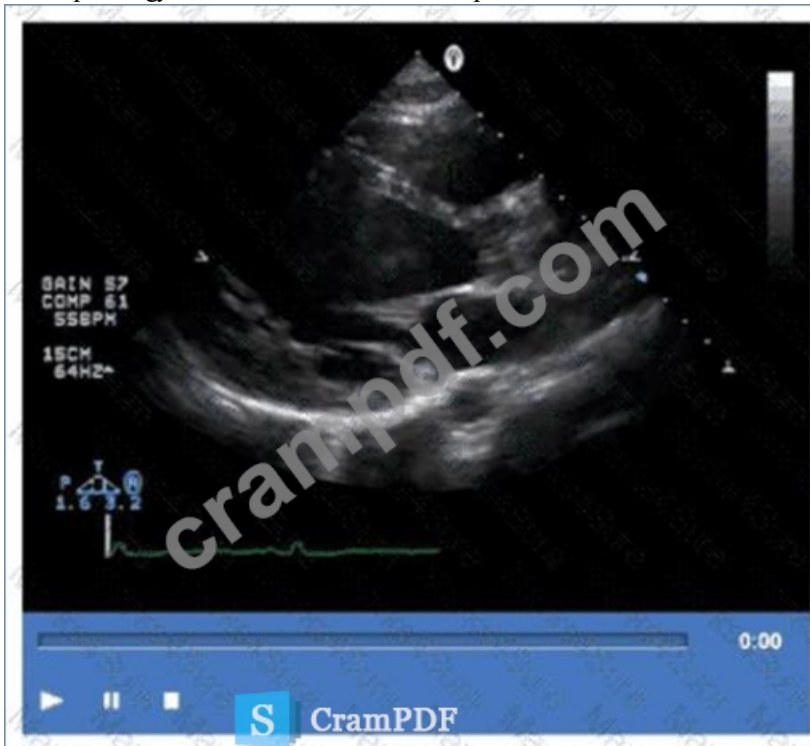Vegetations appear as irregular, mobile masses attached to valve leaflets and are less dense. Tumors and thrombi have different echogenicity and locations (tumors often in atria, thrombi in atrial appendages). MAC is usually more echogenic and localized to the annulus.

This description and differentiation are found in adult echocardiography textbooks and ASE guidelines on cardiac masses and valvular calcifications#16:Textbook of Clinical Echocardiography, 6ep.460-465##12:

ASE Guidelines on Cardiac Massesp.150-160#.

NEW QUESTION # 36

Which pathology is demonstrated in this video clip?



- A. Sarcoidosis
- B. Apical hypertrophic cardiomyopathy
- C. Amyloidosis
- D. Isolated left ventricular noncompaction

Answer: D

Explanation:

The video shows prominent trabeculations with deep intertrabecular recesses communicating with the left ventricular cavity, characteristic of isolated left ventricular noncompaction (LVNC). This congenital cardiomyopathy features a spongy myocardial appearance with thickened noncompacted layers.

Amyloidosis typically presents with thickened, bright myocardium but without prominent trabeculations.

Sarcoidosis involves granulomatous inflammation, and apical hypertrophic cardiomyopathy shows localized hypertrophy without trabecular changes.

This pathology is detailed in the "Textbook of Clinical Echocardiography, 6e", Chapter on Cardiomyopathies and Myocardial Disorders#20:360-365Textbook of Clinical Echocardiography#.

NEW QUESTION # 37

Which procedure is most appropriate for evaluation of an atrial septal defect in the presence of an atrial septal aneurysm?

- A. Cardiac MRI
- B. Transesophageal echocardiogram
- C. Agitated saline contrast echocardiogram

- D. Cardiac catheterization

Answer: B

Explanation:

Transesophageal echocardiography (TEE) provides superior visualization of the atrial septum, especially in the presence of an atrial septal aneurysm, which may obscure transthoracic views. TEE allows detailed anatomic assessment of the atrial septal defect (ASD), its size, and associated structures.

Agitated saline contrast echo is useful for detecting right-to-left shunts but is limited in anatomical delineation in complex cases.

Cardiac MRI and catheterization can provide complementary information but are not first-line for ASD evaluation when TEE is available.

ASE adult congenital heart disease guidelines and echocardiography texts emphasize TEE as the gold standard for ASD evaluation in this setting#12:ASE Adult Congenital Guidelinesp.405-410##16:Textbook of Clinical Echocardiography, 6ep.570-575#.

NEW QUESTION # 38

.....

Young people are facing greater employment pressure. It is imperative to increase your competitiveness. Selecting AE-Adult-Echocardiography learning quiz, you can get more practical skills. First, you will increase your productivity so that you can accomplish more tasks. Second, users who use AE-Adult-Echocardiography Training Materials can pass exams more easily. An international AE-Adult-Echocardiography certificate means that you can get more job opportunities. Seize the opportunity to fully display your strength. Will the future you want be far behind?

AE-Adult-Echocardiography New Braindumps Pdf: <https://www.crampdf.com/AE-Adult-Echocardiography-exam-prep-dumps.html>

- Valid AE-Adult-Echocardiography Exam Forum □ Latest AE-Adult-Echocardiography Exam Fee □ New AE-Adult-Echocardiography Test Questions □ Enter [www.prepawayexam.com] and search for 《 AE-Adult-Echocardiography 》 to download for free □ Books AE-Adult-Echocardiography PDF
- Web-Based Practice Exams to Evaluate ARDMS AE-Adult-Echocardiography Exam Preparation □ Search for [AE-Adult-Echocardiography] and download exam materials for free through □ www.pdfvce.com □ □ Updated AE-Adult-Echocardiography Demo
- Pdf AE-Adult-Echocardiography Exam Dump □ Books AE-Adult-Echocardiography PDF □ Valid AE-Adult-Echocardiography Exam Forum □ Download ➡ AE-Adult-Echocardiography □□□ for free by simply searching on □ www.examcollectionpass.com □ □ Books AE-Adult-Echocardiography PDF
- AE-Adult-Echocardiography Exam Outline □ AE-Adult-Echocardiography Vce File □ AE-Adult-Echocardiography Valid Dumps Demo □ Immediately open 【 www.pdfvce.com 】 and search for ⇒ AE-Adult-Echocardiography ⇐ to obtain a free download □ AE-Adult-Echocardiography Learning Mode
- AE-Adult-Echocardiography Valid Test Practice □ AE-Adult-Echocardiography Latest Torrent □ AE-Adult-Echocardiography Valid Exam Tips □ Search for ▷ AE-Adult-Echocardiography ◁ on ➡ www.exam4labs.com □□□ immediately to obtain a free download □ AE-Adult-Echocardiography Learning Mode
- New AE-Adult-Echocardiography New Dumps Files | Valid ARDMS AE-Adult-Echocardiography: AE Adult Echocardiography Examination 100% Pass □ Search for □ AE-Adult-Echocardiography □ and easily obtain a free download on ☀ www.pdfvce.com □ ☀ □ □ Pdf AE-Adult-Echocardiography Exam Dump
- Instant AE-Adult-Echocardiography Access □ Pdf AE-Adult-Echocardiography Free □ Latest AE-Adult-Echocardiography Exam Fee □ Download [AE-Adult-Echocardiography] for free by simply searching on ➡ www.pdfdumps.com □ □ Valid AE-Adult-Echocardiography Exam Forum
- Free PDF Unparalleled ARDMS - AE-Adult-Echocardiography - AE Adult Echocardiography Examination New Dumps Files □ Open ⇒ www.pdfvce.com ⇐ and search for (AE-Adult-Echocardiography) to download exam materials for free □ AE-Adult-Echocardiography Valid Test Practice
- AE-Adult-Echocardiography Learning Mode □ Instant AE-Adult-Echocardiography Access □ Latest AE-Adult-Echocardiography Exam Fee □ The page for free download of “ AE-Adult-Echocardiography ” on ▷ www.prepawayexam.com ◁ will open immediately □ AE-Adult-Echocardiography Latest Torrent
- Boost Your Confidence with Desktop Practice Test for ARDMS AE-Adult-Echocardiography Exam □ Download 「 AE-Adult-Echocardiography 」 for free by simply entering “ www.pdfvce.com ” website □ AE-Adult-Echocardiography Reliable Exam Tips
- Valid AE-Adult-Echocardiography Exam Materials □ New AE-Adult-Echocardiography Test Questions □ Test AE-Adult-Echocardiography Dumps Pdf □ Easily obtain 《 AE-Adult-Echocardiography 》 for free download through □ www.easy4engine.com □ □ Valid AE-Adult-Echocardiography Exam Forum
- pianowithknight.com, www.stes.tyc.edu.tw, www.stes.tyc.edu.tw, www.stes.tyc.edu.tw, www.stes.tyc.edu.tw, www.stes.tyc.edu.tw,

What's more, part of that CramPDF AE-Adult-Echocardiography dumps now are free: <https://drive.google.com/open?id=1FCvF2hGRNqCK26AzURfewbbFP7Kxb1zF>