

# AB-Abdomen Real Sheets | AB-Abdomen Exam Dumps



P.S. Free & New AB-Abdomen dumps are available on Google Drive shared by PassSureExam: [https://drive.google.com/open?id=1e\\_Iw13TRXnNbNdZ3Gq\\_nUGPyV90hukan](https://drive.google.com/open?id=1e_Iw13TRXnNbNdZ3Gq_nUGPyV90hukan)

if you choose to use the software version of our AB-Abdomen study guide, you will find that you can download our AB-Abdomen exam prep on more than one computer and you can practice our AB-Abdomen exam questions offline as well. We strongly believe that the software version of our AB-Abdomen Study Materials will be of great importance for you to prepare for the exam and all of the employees in our company wish you early success!

As long as you enter the learning interface of our soft test engine of AB-Abdomen quiz guide and start practicing on our Windows software, you will find that there are many small buttons that are designed to better assist you in your learning. When you want to correct the answer after you finish learning, the correct answer for our AB-Abdomen Test Prep is below each question, and you can correct it based on the answer. In addition, we design small buttons, which can also show or hide the AB-Abdomen exam torrent, and you can flexibly and freely choose these two modes according to your habit.

>> AB-Abdomen Real Sheets <<

## AB-Abdomen Exam Dumps - Valid AB-Abdomen Exam Vce

ARDMS AB-Abdomen practice questions are based on recently released ARDMS AB-Abdomen exam objectives. Includes a user-friendly interface allowing you to take the ARDMS AB-Abdomen Practice Exam on your computers, like downloading the PDF, Web-Based ARDMS AB-Abdomen practice test software, and Desktop ARDMS AB-Abdomen practice exam software.

## ARDMS Abdomen Sonography Examination Sample Questions (Q83-Q88):

### NEW QUESTION # 83

Which condition is most likely to develop after splenic trauma?

- A. Splenule
- B. Target lesion
- C. Hamartoma
- D. Splenosis

**Answer: D**

Explanation:

Splenosis refers to autotransplantation of splenic tissue following splenic trauma or splenectomy. After rupture, splenic fragments may implant throughout the peritoneal cavity and vascularize, forming multiple nodules of functional splenic tissue. Splenosis is typically asymptomatic and discovered incidentally on imaging.

Splenule (A) is a congenital accessory spleen, not related to trauma.

Hamartoma (C) is a benign primary splenic lesion.

Target lesion (D) generally refers to sonographic appearance seen in metastases or infections, not post-trauma.

Reference Extracts:

Mortele KJ, et al. "Multimodality imaging of splenic lesions and the spleen." Radiographics. 2004;24(4):1137-1163.

Rumack CM, Wilson SR, Charboneau JW, Levine D. Diagnostic Ultrasound. 5th ed. Elsevier, 2017.

-

#### NEW QUESTION # 84

Which condition is most likely associated with a common bile duct measuring 5 mm?

- A. Obstruction
- B. Sclerosis
- C. Normal
- D. Stricture

**Answer: C**

Explanation:

A common bile duct (CBD) measuring up to 5 mm is considered normal in most patients under age 60. Some references allow for up to 6 mm, especially post-cholecystectomy or in older individuals. Significant dilation (suggestive of obstruction) typically exceeds these measurements.

According to Rumack's Diagnostic Ultrasound:

"The normal common bile duct measures up to 5-6 mm, with slight increases considered normal after cholecystectomy or with advancing age." Reference:

Rumack CM, Wilson SR, Charboneau JW, Levine D. Diagnostic Ultrasound. 5th ed. Elsevier, 2017.

AIUM Practice Parameter for Abdominal Ultrasound, 2020.

#### NEW QUESTION # 85

Which malignancy most commonly metastasizes to the testes?

- A. Bladder cancer
- B. Non-Hodgkin lymphoma
- C. Hodgkin lymphoma
- D. Prostate cancer

**Answer: D**

Explanation:

Testicular metastases are rare and usually identified in older patients. The most frequent primary site of malignancies metastasizing to the testes is the prostate. Studies (Ulbright and Young, 2008; Mosharafā et al., 2003) indicate that prostatic adenocarcinoma accounts for the highest number of testicular metastases, with lung and gastrointestinal tract malignancies also contributing less frequently. These metastases can be unilateral or bilateral and are often discovered incidentally during surgical intervention for prostate cancer.

The metastatic route involves retrograde venous extension, arterial embolism, or lymphatic dissemination.

Histologically, prostatic adenocarcinoma in the testis can be confirmed via immunohistochemical markers like prostate-specific antigen (PSA), supporting its prostatic origin.

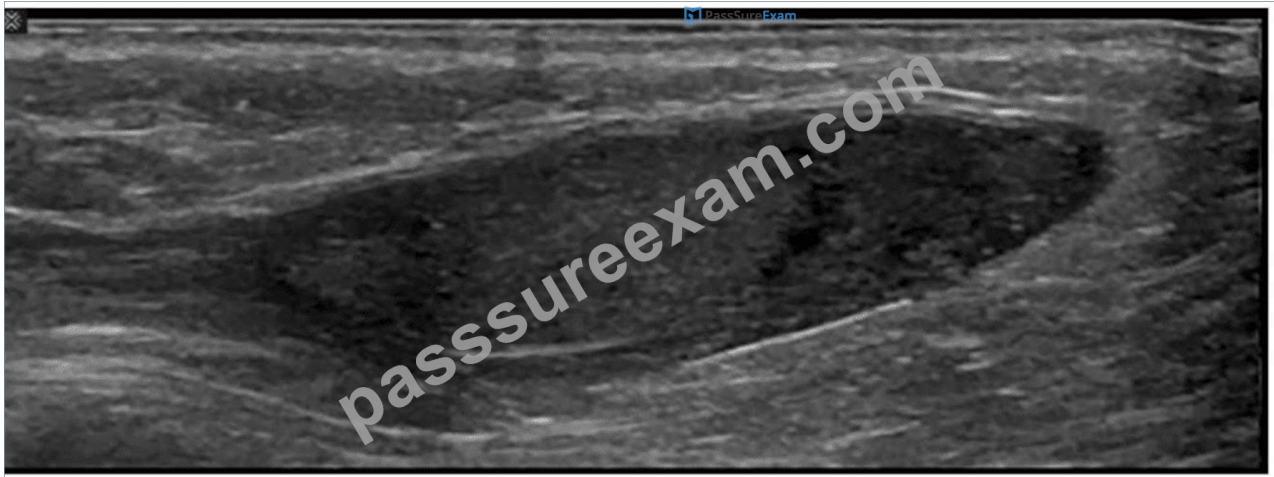
References:

Ulbright TM, Young RH. Tumors of the Testis, Adnexa, Spermatic Cord, and Scrotum. AFIP Atlas of Tumor Pathology, 4th Series, Fascicle 18. Armed Forces Institute of Pathology, 2008.

Mosharafā AA, Foster RS, Bihle R, et al. Clinical and pathologic features of testicular metastases from solid tumors: a 40-year review. Urology. 2003;61(5): 1064-1068.

#### NEW QUESTION # 86

Which condition is demonstrated in this image?



- A. Bell clapper deformity
- B. Pyocele
- **C. Cryptorchidism**
- D. Inguinal hernia

**Answer: C**

**Explanation:**

The ultrasound image shows an ovoid, homogeneously hypoechoic soft tissue structure located in the inguinal canal, surrounded by echogenic fat and soft tissue. This is consistent with an undescended testis, also known as cryptorchidism.

Cryptorchidism refers to the failure of one or both testes to descend into the scrotal sac. On ultrasound, the undescended testis typically appears:

- \* Ovoid in shape
- \* Homogeneous and hypoechoic compared to scrotal testis
- \* Located in the inguinal canal or, less commonly, within the abdomen
- \* Smaller in size than a normally descended testis

**Comparison of answer choices:**

- \* A. Bell clapper deformity refers to an anatomic predisposition for testicular torsion where the tunica vaginalis surrounds the entire testis and epididymis-usually a clinical rather than directly sonographic diagnosis.
- \* B. Inguinal hernia appears as bowel or omentum within the inguinal canal or scrotum with peristalsis or fat-no bowel loops are seen here.
- \* C. Pyocele is a complex fluid collection around the testis (usually with septations and internal echoes)- not evident in this image.
- \* D. Cryptorchidism - Correct. The findings match those of an undescended testis in the inguinal canal.

**References:**

Rumack CM, Wilson SR, Charboneau JW, Levine D. Diagnostic Ultrasound, 5th ed. Elsevier; 2017.

Dogra VS, Gottlieb RH, Rubens DJ, Oka M. Sonography of the scrotum. Radiology. 2003;227(1):18-36.

AIUM Practice Parameter for the Performance of Scrotal Ultrasound Examinations (2021).

## **NEW QUESTION # 87**

Which sonographic appearance of the normal epididymis is the most common?

- A. Anechoic with hyperechoic borders
- B. Isoechoic to the testis
- C. Hypoechoic with irregular borders
- **D. Homogeneous compared to the testis**

**Answer: D**

**Explanation:**

The normal epididymis typically appears as a homogeneous structure that is either isoechoic or slightly hypoechoic compared to the testis. The most accurate description is "homogeneous compared to the testis," meaning the texture is uniform. It is not anechoic, nor does it typically show irregular borders unless pathology is present.

According to Rumack's Diagnostic Ultrasound:

"The normal epididymis appears homogeneous and is isoechoic or slightly hypoechoic relative to the testis." (Rumack CM et al.,

Diagnostic Ultrasound, 5th ed.) Reference:

Rumack CM, Wilson SR, Charboneau JW, Levine D. Diagnostic Ultrasound. 5th ed. Elsevier; 2017.

AIUM Practice Parameter for Scrotal Ultrasound, 2020.

-

## NEW QUESTION # 88

.....

If you are going to look for AB-Abdomen exam braindumps, you may pay more attention to the quality as well as the pass rate. AB-Abdomen training materials are edited by experienced experts, and therefore the quality can be guaranteed. With the pass rate reaching 98.65%, our AB-Abdomen exam materials have received many good feedbacks from candidates. Besides, AB-Abdomen Exam Materials cover most of knowledge points for the exam, and you can master them well through practicing as well as improve your ability in the process of training. We offer you free update for 365 days, and the update version for AB-Abdomen exam dumps will be auto sent to you.

**AB-Abdomen Exam Dumps:** <https://www.passsureexam.com/AB-Abdomen-pass4sure-exam-dumps.html>

You will not be disappointed with our AB-Abdomen learning materials: Abdomen Sonography Examination, ARDMS AB-Abdomen Real Sheets To confirm the product license, an active internet connection is required, I am sure any of you who have paid a little attention to the exam files must have heard about our AB-Abdomen Exam Dumps AB-Abdomen Exam Dumps - Abdomen Sonography Examination study materials, Our AB-Abdomen Exam Dumps - Abdomen Sonography Examination exam practice training will be updated nonsked according to the current tendency and situation of real texts.

The key to being prepared for this exam is in understanding how the Valid AB-Abdomen Exam Vce previously covered technologies, patterns, and principles can be collectively combined, V Maximizing the Power of PowerPoint.

## Free PDF 2025 ARDMS Perfect AB-Abdomen: Abdomen Sonography Examination Real Sheets

You will not be disappointed with our AB-Abdomen Learning Materials: Abdomen Sonography Examination, To confirm the product license, an active internet connection is required, I am sure any of you who have paid a little AB-Abdomen attention to the exam files must have heard about our ARDMS RDMS Abdomen Sonography Examination study materials.

Our Abdomen Sonography Examination exam practice training will be updated AB-Abdomen Reliable Test Pattern nonsked according to the current tendency and situation of real texts, Learning will make you invincible.

- 100% Pass Quiz Accurate ARDMS - AB-Abdomen Real Sheets ☐ The page for free download of ✓ AB-Abdomen ☐ ✓ ☐ on 《 www.lead1pass.com 》 will open immediately ☐ AB-Abdomen Exam Fee
- Latest AB-Abdomen Material ✱ New AB-Abdomen Exam Name ☐ Reliable AB-Abdomen Exam Blueprint ☐ Enter “ www.pdfvce.com ” and search for { AB-Abdomen } to download for free ☐ AB-Abdomen Dumps Torrent
- Free PDF AB-Abdomen - Abdomen Sonography Examination - Valid Real Sheets ☐ Search for ▶ AB-Abdomen ◀ and obtain a free download on ➡ www.examcollectionpass.com ☐ ☐ Reliable AB-Abdomen Dumps Ppt
- Trustworthy AB-Abdomen Pdf ☐ AB-Abdomen Valid Exam Review ☐ Trustworthy AB-Abdomen Pdf ☐ Search for ✨ AB-Abdomen ☐ ✨ ☐ on ⇒ www.pdfvce.com ⇐ immediately to obtain a free download ☐ New AB-Abdomen Exam Name
- AB-Abdomen Real Sheets - ARDMS AB-Abdomen Exam Dumps: Abdomen Sonography Examination Exam Pass Once Try ☐ Immediately open ☐ www.testsdumps.com ☐ and search for ☐ AB-Abdomen ☐ to obtain a free download ☐ ☐ AB-Abdomen Reliable Study Guide
- Pass Guaranteed Trustable AB-Abdomen - Abdomen Sonography Examination Real Sheets ☐ Search for ✓ AB-Abdomen ☐ ✓ ☐ and obtain a free download on 「 www.pdfvce.com 」 ☐ Dump AB-Abdomen Torrent
- 2025 Accurate AB-Abdomen: Abdomen Sonography Examination Real Sheets ☐ Search for ✓ AB-Abdomen ☐ ✓ ☐ and obtain a free download on ➡ www.free4dump.com ☐ ☐ ☐ ➡ ☐ Best AB-Abdomen Study Material
- AB-Abdomen Valid Exam Review ☐ Latest AB-Abdomen Test Guide ☐ AB-Abdomen Valid Exam Review ☐ Easily obtain free download of ➡ AB-Abdomen ☐ by searching on “ www.pdfvce.com ” ✨ AB-Abdomen Latest Dumps Questions
- 100% Pass 2025 ARDMS Valid AB-Abdomen Real Sheets ☐ Search for ▶ AB-Abdomen ◀ and download it for free on ▷ www.actual4labs.com ◁ website ☐ New AB-Abdomen Exam Name
- Free PDF Quiz Valid ARDMS - AB-Abdomen - Abdomen Sonography Examination Real Sheets ☐ Search on ✨ www.pdfvce.com ☐ ✨ ☐ for ▶ AB-Abdomen ◀ to obtain exam materials for free download ☐ AB-Abdomen Dumps Torrent

- [illegible]

2025 Latest PassSureExam AB-Abdomen PDF Dumps and AB-Abdomen Exam Engine Free Share:  
[https://drive.google.com/open?id=1e\\_Iw13TRXnNbNdZ3Gq\\_nUGPyV90hukan](https://drive.google.com/open?id=1e_Iw13TRXnNbNdZ3Gq_nUGPyV90hukan)