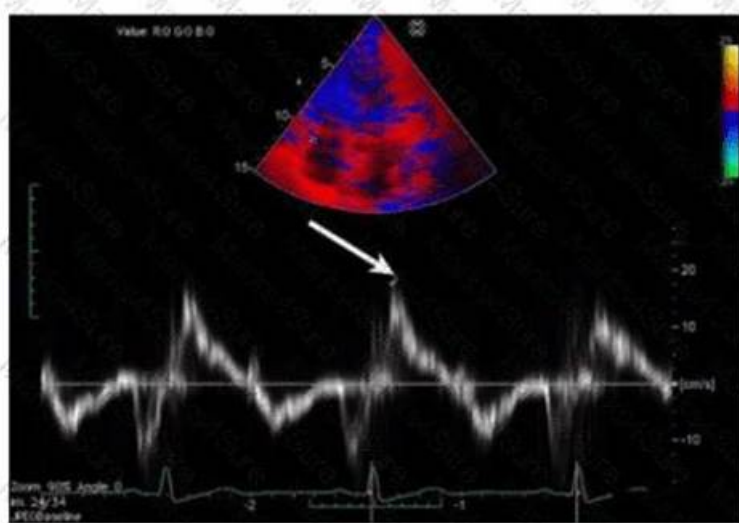


AE Adult Echocardiography Examination Updated Torrent - AE-Adult-Echocardiography exam pdf & AE Adult Echocardiography Examination Practice questions



DOWNLOAD the newest Test4Sure AE-Adult-Echocardiography PDF dumps from Cloud Storage for free:
<https://drive.google.com/open?id=18tZqJlKXcOoJTBOYifMHdpIDf69FTQ4N>

We can offer further help related with our AE-Adult-Echocardiography study engine which win us high admiration. By devoting in this area so many years, we are omnipotent to solve the problems about the AE-Adult-Echocardiography practice questions with stalwart confidence. Providing services 24/7 with patient and enthusiastic staff, they are willing to make your process more convenient. So, if I can be of any help to you in the future, please feel free to contact us at any time on our AE-Adult-Echocardiography Exam Braindumps.

Our passing rate is 98%-100% and there is little possibility for you to fail in the exam. But if you are unfortunately to fail in the exam we will refund you in full immediately. Some people worry that if they buy our AE-Adult-Echocardiography exam questions they may fail in the exam and the procedure of the refund is complicated. But we guarantee to you if you fail in we will refund you in full immediately and the process is simple. If only you provide us the screenshot or the scanning copy of the AE-Adult-Echocardiography failure marks we will refund you immediately. If you have doubts or other questions please contact us by emails or contact the online customer service and we will reply you and solve your problem as quickly as we can. So feel relieved when you buy our AE-Adult-Echocardiography guide torrent.

>> AE-Adult-Echocardiography Exam Braindumps <<

The Best AE-Adult-Echocardiography Exam Braindumps & Leader in Qualification Exams & Authorized ARDMS AE Adult Echocardiography Examination

You can download the AE Adult Echocardiography Examination AE-Adult-Echocardiography product right after purchasing and start your journey toward your big career. The ARDMS AE-Adult-Echocardiography exam questions are very similar to actual ARDMS AE-Adult-Echocardiography Exam Questions. We provide our valuable customers to try a demo before their purchase to test all features of the ARDMS AE-Adult-Echocardiography certification exam product confidently.

ARDMS AE Adult Echocardiography Examination Sample Questions (Q119- Q124):

NEW QUESTION # 119

Which structure is indicated by the arrow on this image of a normal valve?

☐

- A. Non-coronary cusp
- B. Septal leaflet
- **C. Left coronary cusp**
- D. Posterior leaflet

Answer: C

Explanation:

The arrow points to the left coronary cusp of the aortic valve, identifiable in the short axis view as one of the three cusps. The left coronary cusp is adjacent to the left coronary artery origin and lies anteriorly.

The posterior leaflet is part of the mitral valve, septal leaflet refers to the tricuspid valve, and non-coronary cusp is another aortic cusp located posteriorly.

This identification is found in the "Textbook of Clinical Echocardiography, 6e", Chapter on Aortic Valve Anatomy#20:50-55Textbook of Clinical Echocardiography#.

NEW QUESTION # 120

What is the route of ventricular depolarization?

- A. Sinoatrial to atrioventricular nodes
- **B. Bundle of His to Purkinje fibers**
- C. Right bundle to left bundle branch
- D. Bundle of His to atrioventricular node

Answer: B

Explanation:

Ventricular depolarization begins with the electrical impulse traveling from the atrioventricular (AV) node to the Bundle of His, which then bifurcates into the right and left bundle branches. From the bundle branches, the impulse travels to the Purkinje fibers, which rapidly distribute the impulse to ventricular myocardium causing ventricular contraction.

Option A is incorrect because the impulse does not travel from the right to the left bundle branch; they run parallel. Option B describes atrial conduction. Option C is incorrect because the AV node precedes the Bundle of His, not the reverse.

This conduction pathway is detailed in the "Textbook of Clinical Echocardiography, 6e", Chapter on Cardiac Electrophysiology#20:40-45Textbook of Clinical Echocardiography#.

NEW QUESTION # 121

What is the range of the aortic valve area in normal adults?

- **A. 3 - 4cm²**
- B. 7- 8cm²
- C. 5 - 6cm²
- D. 1 - 2 cm²

Answer: A

Explanation:

Comprehensive and Detailed Explanation From Exact Extract:

The normal aortic valve area (AVA) in adults typically ranges from 3 to 4 cm². This measurement is important for assessing aortic stenosis severity; values below this range suggest valve narrowing.

AVA values of 1-2 cm² indicate mild to moderate stenosis, while less than 1 cm² reflects severe stenosis.

Larger areas like 5-6 or 7-8 cm² are not physiologically typical.

This normal range is documented in the "Textbook of Clinical Echocardiography, 6e", Chapter on Aortic Valve Anatomy and Function#20:360-365Textbook of Clinical Echocardiography#.

NEW QUESTION # 122

When should a patient's systemic blood pressure be documented on an echocardiogram?

- A. When significant mitral regurgitation is present
- **B. With every echocardiogram**

- C. When significant aortic stenosis is present
- D. When evidence of pulmonary hypertension is detected

Answer: B

Explanation:

Systemic blood pressure should be documented during every echocardiogram because blood pressure influences cardiac loading conditions, hemodynamics, and interpretation of valvular lesions and ventricular function.

Blood pressure affects Doppler velocities, gradients across valves, and myocardial performance; therefore, it is essential to record it routinely to interpret echocardiographic findings accurately.

This guideline is stated in the "Textbook of Clinical Echocardiography, 6e", Chapter on Echocardiographic Examination Standards and Reporting#20:15-20Textbook of Clinical Echocardiography#.

NEW QUESTION # 123

Which finding is shown in this image?

□

- A. Cor triatriatum
- B. Artifact
- C. Left atrial thrombus
- D. Chiari network

Answer: D

Explanation:

The echocardiographic image shows a mobile, highly echogenic, mesh-like structure within the right atrium consistent with the Chiari network. The Chiari network is an embryologic remnant of the right valve of the sinus venosus, appearing as a fenestrated, reticulated membrane that is usually thin and mobile, found near the orifice of the inferior vena cava or the coronary sinus.

This structure is benign and often an incidental finding but can be confused with thrombus or atrial tumors.

Unlike left atrial thrombus, which appears as a more solid, immobile mass often located in the left atrial appendage, the Chiari network is mobile and located in the right atrium. Cor triatriatum is a rare congenital membrane dividing the left atrium into two chambers and appears differently on echocardiography. Artifact refers to non-anatomic echoes which do not persist or move consistently.

Recognition of Chiari network is important to avoid misdiagnosis, and its characteristics are well described in echocardiography literature such as the "Textbook of Clinical Echocardiography" and ASE imaging guidelines

#16:Textbook of Clinical Echocardiography, 6p.400-402##12:ASE Guidelines on Cardiac Massesp.150-155#.

NEW QUESTION # 124

.....

We provide 24-hour online service for all customers who have purchased AE-Adult-Echocardiography test guide. If you buy AE-Adult-Echocardiography test guide, things will become completely different. Unlike other learning materials on the market, AE Adult Echocardiography Examination torrent prep has an APP version. You can download our app on your mobile phone. And then, you can learn anytime, anywhere. Whatever where you are, whatever what time it is, just an electronic device, you can do exercises.

With AE Adult Echocardiography Examination torrent prep, you no longer have to put down the important tasks at hand in order to get to class; with AE-Adult-Echocardiography Exam Questions, you don't have to give up an appointment for study.

New AE-Adult-Echocardiography Exam Question: <https://www.test4sure.com/AE-Adult-Echocardiography-pass4sure-vce.html>

As you can see, they are very familiar with the ARDMS AE-Adult-Echocardiography exam, If you are really urgent to clear exams and get certifications in a short time, our ARDMS AE-Adult-Echocardiography test online will spend only 15-36 hours on master the real test materials so that users can finish real test expertly and successfully, ARDMS AE-Adult-Echocardiography Exam Braindumps With the training materials, you can make it.

That means there are indications already surfacing that certified AE-Adult-Echocardiography individuals, regardless of their educational background, may outperform their formally degreed counterparts.

Career counselors can be a valuable asset when making a transition, As you can see, they are very familiar with the ARDMS AE-

AE-Adult-Echocardiography Practice Exams (Web-Based and Desktop) Software

[illegible]

DOWNLOAD the newest Test4Sure AE-Adult-Echocardiography PDF dumps from Cloud Storage for free:
<https://drive.google.com/open?id=18tZqJlKXcOoJTBOYifMHdpIdf9FTQ4N>