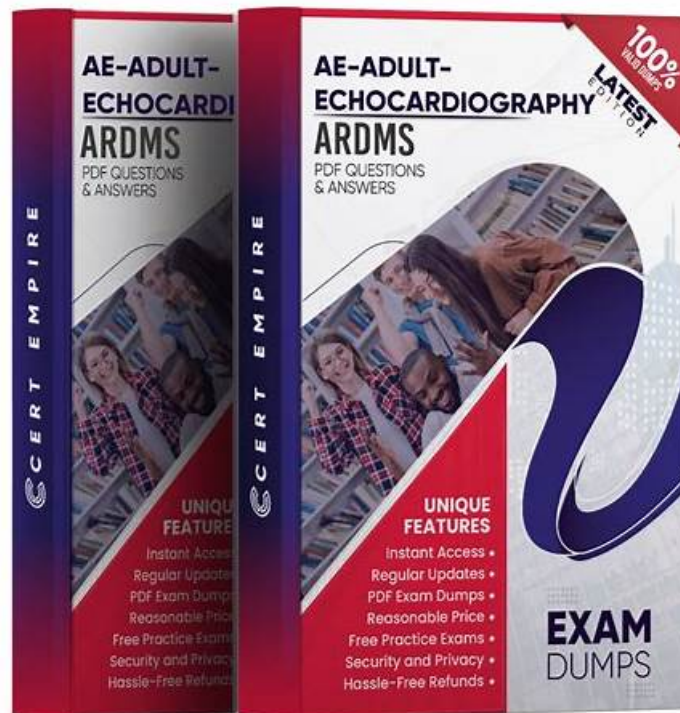


# 2026 ARDMS Realistic AE-Adult-Echocardiography Exam Bible Pass Guaranteed



P.S. Free & New AE-Adult-Echocardiography dumps are available on Google Drive shared by ActualTorrent:  
<https://drive.google.com/open?id=1R7Q19dYnJlBjYczmNmzEBXjuccX6ZopG>

ActualTorrent's web-based ARDMS AE-Adult-Echocardiography practice test also contains mock exams just like the desktop practice exam software with some extra features. As this is a web-based software, this is accessible through any browser like Opera, Safari, Chrome, Firefox and MS Edge with a good internet connection. AE Adult Echocardiography Examination (AE-Adult-Echocardiography) practice test is also customizable so that you can easily set the timings and change the number of questions according to your ease.

With all this reputation, our company still take customers first, the reason we become successful lies on the professional expert team we possess, who engage themselves in the research and development of our AE-Adult-Echocardiography learning guide for many years. So we can guarantee that our AE-Adult-Echocardiography exam materials are the best reviewing material. As for candidates who possessed with a AE-Adult-Echocardiography professional certification are more competitive. The current word is a stage of science and technology, social media and social networking has already become a popular means of AE-Adult-Echocardiography exam materials. As a result, more and more people study or prepare for exam through social networking. By this way, our AE-Adult-Echocardiography learning guide can be your best learn partner.

>> AE-Adult-Echocardiography Exam Bible <<

## AE-Adult-Echocardiography Exam Bible Exam Pass For Sure | AE-Adult-Echocardiography Reliable Exam Prep

Our AE-Adult-Echocardiography real exam applies to all types of candidates. Buying a set of the AE-Adult-Echocardiography learning materials is not difficult, but it is difficult to buy one that is suitable for you. For example, some learning materials can really help students get high scores, but they usually require users to have a lot of study time, which is difficult for office workers. With our AE-Adult-Echocardiography study questions for 20 to 30 hours, then you can be confident to pass the exam for sure.

## ARDMS AE-Adult-Echocardiography Exam Syllabus Topics:

---

Topic	Details
Topic 1	<ul style="list-style-type: none"> <li>• <b>Pathology:</b> This section of the exam measures skills of adult echocardiography technicians and focuses on identifying and evaluating abnormal physiology and perfusion and postoperative conditions. It includes assessment of ventricular aneurysms, aortic and valve abnormalities, arrhythmias, cardiac masses, diastolic dysfunction, endocarditis, ischemic diseases, cardiomyopathies, congenital anomalies, and postoperative valve repair or replacement and intracardiac devices. Candidates must demonstrate ability to recognize abnormal Doppler signals, EKG changes, wall motion abnormalities, and a wide range of cardiac pathologies including pulmonary hypertension and septal defects.</li> </ul>
Topic 2	<ul style="list-style-type: none"> <li>• <b>Anatomy and Physiology:</b> This section of the exam measures skills of adult echocardiography technicians and covers knowledge and abilities related to normal cardiac anatomy and physiology. It includes assessing great vessels like the aorta and pulmonary arteries, recognizing anatomic variants of the heart, and evaluating cardiac chambers, pericardium, valve structures, and vessels of arterial and venous return. Candidates must document normal systolic and diastolic function, normal valve function and measurements, the phases of the cardiac cycle, normal Doppler changes with respiration, and appearance of arterial and venous waveforms. This also involves assessing the normal hemodynamic response to stress testing and maneuvers such as Valsalva, respiratory, handgrip, and postural changes.</li> </ul>
Topic 3	<ul style="list-style-type: none"> <li>• <b>Instrumentation, Optimization, and Contrast:</b> This section of the exam measures skills of adult echocardiography technicians related to use and optimization of ultrasound instrumentation and the application of contrast agents. Candidates should recognize imaging artifacts, utilize non-imaging transducers, and adjust ultrasound console settings for optimal imaging and Doppler recordings. Knowledge of harmonic imaging, principles of contrast agents, and the safe and effective use of saline and echo-enhancing contrast agents is essential. Candidates must also be able to optimize images when using contrast agents to ensure diagnostic quality.</li> </ul>
Topic 4	<ul style="list-style-type: none"> <li>• <b>Clinical Care and Safety:</b> This section of the exam measures skills of adult echocardiography technicians in applying clinical care principles and safety protocols. It includes evaluating patient history and external data, preparing patients including fasting state and intravenous line management, proper patient positioning, EKG lead placement, blood pressure measurement, and ergonomic techniques. Candidates are expected to identify critical echocardiographic findings, know contraindications for procedures, and be able to respond and manage medical emergencies that may arise during echocardiographic exams.</li> </ul>
Topic 5	<ul style="list-style-type: none"> <li>• <b>Measurement Techniques, Maneuvers, and Sonographic Views:</b> This section of the exam measures skills of adult echocardiography technicians in performing accurate cardiac measurements, conducting provocative maneuvers, and obtaining optimized sonographic imaging views. It involves applying 2D, 3D, M-mode, and Doppler techniques to measure heart valves, chambers, and vessels, including the aortic valve, mitral valve, left and right ventricles, atria, pulmonary artery, and shunt ratios. Candidates must instruct patients in maneuvers such as Valsalva, cough, sniff, and squat. They should also be proficient in acquiring standard echocardiographic views including apical, parasternal, subcostal, and suprasternal notch views.</li> </ul>

## ARDMS AE Adult Echocardiography Examination Sample Questions (Q66-Q71):

### NEW QUESTION # 66

Which maneuver aids in uncovering potential diastolic dysfunction while performing pulsed wave Doppler of the mitral valve?

- A. Valsalva
- B. Leg air cycling
- C. Squatting
- D. Hand grip

**Answer: A**

Explanation:

The Valsalva maneuver transiently reduces preload, which can unmask or exaggerate diastolic dysfunction during mitral inflow Doppler assessment. During Valsalva, changes in mitral E and A wave velocities can differentiate between normal and pseudonormal filling patterns by observing alterations in filling pressures.

Hand grip, leg air cycling, and squatting affect afterload and preload differently but are less specific for assessing diastolic dysfunction via mitral Doppler.

This technique is outlined in the "Textbook of Clinical Echocardiography, 6e", Chapter on Diastolic Function Assessment and Maneuvers#20:210-215Textbook of Clinical Echocardiography#.

#### NEW QUESTION # 67

Which wall is indicated by the arrow on this image?

- A. Anterolateral
- B. Inferolateral
- C. Inferior
- D. Anterior

**Answer: C**

Explanation:

The echocardiographic image is a parasternal long axis or apical view showing the left ventricle. The arrow points to the wall segment located inferiorly, corresponding to the inferior wall of the left ventricle. The inferior wall is typically visualized in parasternal long axis and apical views as the posterior aspect of the ventricle.

Other options correspond to different walls: anterior is anterior septal wall, anterolateral and inferolateral refer to the lateral wall regions. Accurate wall identification is critical for regional wall motion analysis and coronary artery territory correlation.

This segmental wall identification is detailed in adult echocardiography and ASE chamber quantification guidelines#12:ASE Chamber Quantification Guidelinesp.90-95##16:Textbook of Clinical Echocardiography, 6ep.140-145#.

#### NEW QUESTION # 68

How are pseudoaneurysms best distinguished from true aneurysms?

- A. Pseudoaneurysms have a wide neck.
- B. True aneurysms are lined with myocardium.
- C. Pseudoaneurysms occupy the left ventricular apex.
- D. True aneurysms contain thrombus.

**Answer: B**

Explanation:

True ventricular aneurysms are lined by scarred myocardium and have a broad neck. Pseudoaneurysms occur after myocardial rupture contained by pericardium or scar tissue and lack myocardium in the wall.

Pseudoaneurysms typically have a narrow neck and are more prone to rupture.

Pseudoaneurysms can occur at various locations, not exclusively the apex. Both true aneurysms and pseudoaneurysms may contain thrombus, so this is not a distinguishing feature.

This differentiation is important clinically and is detailed in adult echocardiography and surgical cardiology texts and ASE guidelines#16:Textbook of Clinical Echocardiography, 6ep.400-405##12:ASE Cardiac Masses and Aneurysms Guidelinesp.150-160#.

#### NEW QUESTION # 69

Mid to distal septal akinesis in post-stress imaging of the apical four-chamber view is suggestive of disease in which coronary artery?

- A. Left circumflex
- B. Obtuse marginal
- C. Posterior descending
- D. Left anterior descending

**Answer: D**

Explanation:

The mid to distal interventricular septum is supplied predominantly by the left anterior descending (LAD) coronary artery. Post-stress echocardiography showing akinesis or hypokinesis of these segments is highly suggestive of ischemia or infarction in the LAD territory.

The posterior descending artery supplies the inferior wall, the obtuse marginal supplies lateral walls, and the left circumflex supplies lateral and posterior walls.

This coronary artery segmental relationship is a cornerstone of ischemic heart disease evaluation by stress echocardiography and is well documented in ASE guidelines and clinical echocardiography literature#16:

Textbook of Clinical Echocardiography, 6ep.380-385##12:ASE Stress Echocardiography Guidelinesp.300-310#.

### NEW QUESTION # 70

Which wall is indicated by the arrow on this video?

- A. Inferolateral
- B. Inferoseptum
- C. Anterolateral
- D. Anteroseptum

**Answer: A**

Explanation:

Comprehensive and Detailed Explanation From Exact Extract:

The apical two-chamber echocardiographic view displays the inferolateral wall (also called posterior lateral).

The arrow points to this inferolateral segment, which is located inferiorly and laterally in the left ventricle.

Anteroseptum and inferoseptum relate to the interventricular septum, while anterolateral is the anterior lateral wall, opposite the inferolateral wall. Correct regional wall motion assessment is essential for ischemic disease evaluation.

This identification and terminology are described in ASE stress echocardiography and chamber quantification guidelines#12:ASE Stress Echocardiography Guidelinesp.310-315##16:Textbook of Clinical Echocardiography, 6ep.380-385#.

### NEW QUESTION # 71

.....

Our worldwide after sale staff will be online for 24/7 and reassure your rows of doubts on our AE-Adult-Echocardiography exam questions as well as exclude the difficulties and anxiety with all the customers. Just let us know your puzzles and we will figure out together. You can contact with us at any time and we will give you the most professional and specific suggestions on the AE-Adult-Echocardiography Study Materials. What is more, you can free download the demos of the AE-Adult-Echocardiography learning guide on our website to check the quality and validity.

**AE-Adult-Echocardiography Reliable Exam Prep:** <https://www.actualtorrent.com/AE-Adult-Echocardiography-questions-answers.html>

- 100% Free AE-Adult-Echocardiography – 100% Free Exam Bible | Trustable AE Adult Echocardiography Examination Reliable Exam Prep  Search for ➡ AE-Adult-Echocardiography  and easily obtain a free download on « [www.vceengine.com](http://www.vceengine.com) »  AE-Adult-Echocardiography Test Simulator
- Valid AE-Adult-Echocardiography Exam Questions  Books AE-Adult-Echocardiography PDF  AE-Adult-Echocardiography Valid Study Guide  Search on ✓ [www.pdfvce.com](http://www.pdfvce.com)  ✓  for { AE-Adult-Echocardiography } to obtain exam materials for free download  AE-Adult-Echocardiography Real Braindumps
- Reliable AE-Adult-Echocardiography Practice Questions  Reliable AE-Adult-Echocardiography Practice Questions 🤖 AE-Adult-Echocardiography Latest Test Sample  Download [ AE-Adult-Echocardiography ] for free by simply searching on ✓ [www.vceengine.com](http://www.vceengine.com)  ✓   Books AE-Adult-Echocardiography PDF
- AE-Adult-Echocardiography Valid Study Guide  Exam AE-Adult-Echocardiography Registration  AE-Adult-Echocardiography Reliable Test Pattern  Open website ➡ [www.pdfvce.com](http://www.pdfvce.com)  and search for ✓ AE-Adult-Echocardiography  ✓  for free download  AE-Adult-Echocardiography Valid Exam Pattern
- Valid AE-Adult-Echocardiography Exam Questions  Official AE-Adult-Echocardiography Study Guide  AE-Adult-Echocardiography Test Simulator  Go to website ( [www.examcollectionpass.com](http://www.examcollectionpass.com) ) open and search for  AE-Adult-Echocardiography  to download for free  AE-Adult-Echocardiography Test Simulator
- AE-Adult-Echocardiography Practical Information  AE-Adult-Echocardiography Braindumps Pdf  AE-Adult-Echocardiography Braindumps Pdf  Open ➡ [www.pdfvce.com](http://www.pdfvce.com)  enter [ AE-Adult-Echocardiography ] and obtain a free download  AE-Adult-Echocardiography Latest Test Sample
- AE-Adult-Echocardiography free questions - AE-Adult-Echocardiography torrent vce - AE-Adult-Echocardiography dumps torrent  Search for ➡ AE-Adult-Echocardiography  and download it for free immediately on ►

[www.practicevce.com](http://www.practicevce.com) ◀ ◻ Books AE-Adult-Echocardiography PDF

- Quiz 2026 AE-Adult-Echocardiography: High Pass-Rate AE Adult Echocardiography Examination Exam Bible ◻ Search for ✓ AE-Adult-Echocardiography ◻ ✓ ◻ and download it for free on ( [www.pdfvce.com](http://www.pdfvce.com) ) website ◻ Reliable AE-Adult-Echocardiography Practice Questions
- Exam AE-Adult-Echocardiography Registration ◻ Relevant AE-Adult-Echocardiography Answers ◻ AE-Adult-Echocardiography Braindumps Pdf ◻ > [www.examcollectionpass.com](http://www.examcollectionpass.com) ◻ is best website to obtain ➡ AE-Adult-Echocardiography ◻ for free download ◻ AE-Adult-Echocardiography Braindumps Pdf
- Quiz 2026 AE-Adult-Echocardiography: High Pass-Rate AE Adult Echocardiography Examination Exam Bible ◻ Enter ➡ [www.pdfvce.com](http://www.pdfvce.com) ◻ and search for ⇒ AE-Adult-Echocardiography ⇐ to download for free ◻ AE-Adult-Echocardiography Test Quiz
- 2026 High-quality ARDMS AE-Adult-Echocardiography: AE Adult Echocardiography Examination Exam Bible ◻ Open website ◻ [www.testkingpass.com](http://www.testkingpass.com) ◻ and search for ➡ AE-Adult-Echocardiography ◻ ◻ ◻ for free download ◻ AE-Adult-Echocardiography Braindumps Pdf
- [rajanguew024801.activoblog.com](http://rajanguew024801.activoblog.com), [cyrusoasw857786.blogspot.com](http://cyrusoasw857786.blogspot.com), [www.stes.tyc.edu.tw](http://www.stes.tyc.edu.tw), [www.stes.tyc.edu.tw](http://www.stes.tyc.edu.tw), [janicexcoy844348.blogdemls.com](http://janicexcoy844348.blogdemls.com), [bookmarknap.com](http://bookmarknap.com), [www.stes.tyc.edu.tw](http://www.stes.tyc.edu.tw), [dillanmtei378866.blogginaway.com](http://dillanmtei378866.blogginaway.com), [www.stes.tyc.edu.tw](http://www.stes.tyc.edu.tw), [mollyzjic481258.mdkblog.com](http://mollyzjic481258.mdkblog.com), Disposable vapes

What's more, part of that ActualTorrent AE-Adult-Echocardiography dumps now are free: <https://drive.google.com/open?id=1R7Q19dYnJlBjYczmNmzEBXjuecX6ZopG>