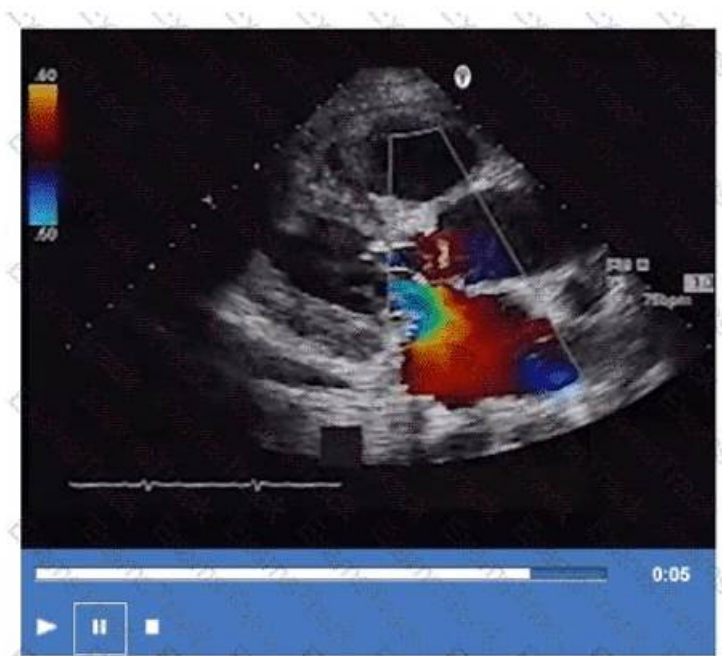


Valid AE-Adult-Echocardiography Test Sample Will Be Your Best Friend to Pass AE Adult Echocardiography Examination



BONUS!!! Download part of PassLeader AE-Adult-Echocardiography dumps for free: <https://drive.google.com/open?id=1aLUkzuxfORTZWWeAniT6eVmlJd7VcwYV>

False AE-Adult-Echocardiography practice materials deprive you of valuable possibilities of getting success. As professional model company in this line, success of the AE-Adult-Echocardiography training guide will be a foreseeable outcome. Even some nit-picking customers cannot stop practicing their high quality and accuracy. We are intransigent to the quality issue and you can totally be confident about their proficiency sternly. Choosing our AE-Adult-Echocardiography Exam Questions is equal to choosing success.

As we all know, practice makes perfect. It's also applied into preparing for the exam. AE-Adult-Echocardiography training materials of us contain both quality and quantity, and you will get enough practice if you choose us. In addition, AE-Adult-Echocardiography exam cram cover most of the knowledge points for the exam, and you can master the major knowledge points for the exam as well as improve your professional ability in the process of learning. We are pass guarantee and money back guarantee if you fail to pass your exam by using AE-Adult-Echocardiography Exam Dumps of us. Online and offline service are available by us, if you have any questions, you can consult us.

>> Valid AE-Adult-Echocardiography Test Sample <<

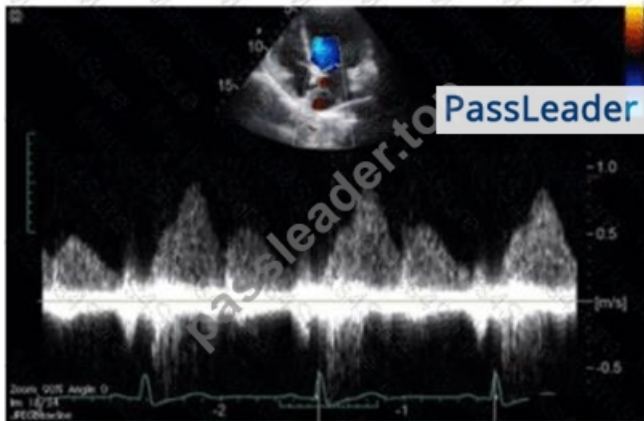
Pass Guaranteed 2026 High Hit-Rate AE-Adult-Echocardiography: Valid AE Adult Echocardiography Examination Test Sample

A AE Adult Echocardiography Examination will not only expand your knowledge but it will polish your abilities as well to advance successfully in the world of ARDMS. Real ARDMS AE-Adult-Echocardiography Exam QUESTIONS certification increases your commitment and professionalism by giving you all the knowledge necessary to work in a professional setting. We have heard from thousands of people who say that using the authentic and Reliable AE-Adult-Echocardiography Exam Dumps was the only way they were able to pass the AE-Adult-Echocardiography.

ARDMS AE Adult Echocardiography Examination Sample Questions (Q87-Q92):

NEW QUESTION # 87

Which of the following does this Image represent?



- A. Mitral valve inflow
- B. Pulmonary vein Doppler
- C. Hepatic vein Doppler
- D. Tricuspid valve inflow

Answer: C

Explanation:

Comprehensive and Detailed Explanation From Exact Extract:

The image shows a pulsed-wave Doppler waveform with respiratory phasicity and distinct forward and reversed flow components characteristic of hepatic vein flow patterns. Hepatic vein Doppler typically displays a biphasic waveform with systolic (S) and diastolic (D) forward flow toward the heart and brief reversed flow during atrial contraction (A wave reversal), reflecting right atrial pressure changes.

Mitral and tricuspid inflow Doppler patterns show distinct E and A waves representing early and late diastolic ventricular filling but do not have the same flow reversal pattern. Pulmonary vein Doppler waveforms also differ, showing systolic and diastolic forward flows into the left atrium without the prominent reversed flow seen here.

The hepatic vein Doppler is commonly used in echocardiography to assess right atrial pressure and compliance, especially in conditions like constrictive pericarditis and right heart failure, where characteristic flow reversals and expiratory changes are observed.

This pattern and its clinical significance are detailed in adult echocardiography references, including the "Textbook of Clinical Echocardiography" and ASE guidelines on Doppler imaging#16:Hepatic Vein DopplerTextbook of Clinical Echocardiography, 6e##12:ASE Doppler Guidelinesp.95-100#.

NEW QUESTION # 88

Which maneuver aids in uncovering potential diastolic dysfunction while performing pulsed wave Doppler of the mitral valve?

- A. Valsalva
- B. Leg air cycling
- C. Squatting
- D. Hand grip

Answer: A

Explanation:

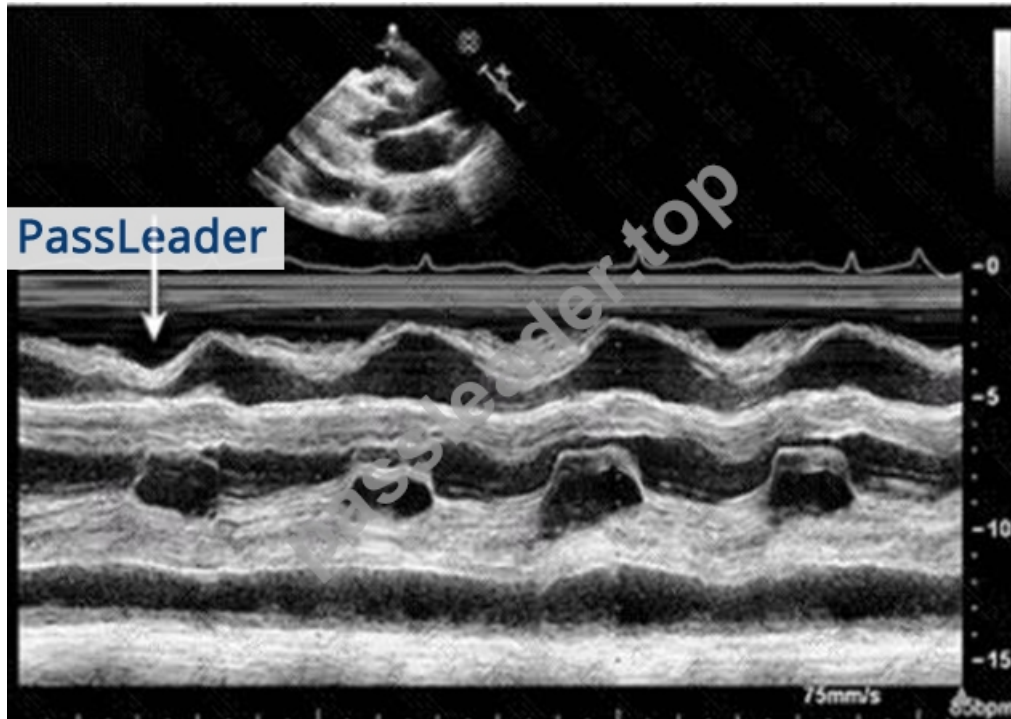
The Valsalva maneuver transiently reduces preload, which can unmask or exaggerate diastolic dysfunction during mitral inflow Doppler assessment. During Valsalva, changes in mitral E and A wave velocities can differentiate between normal and pseudonormal filling patterns by observing alterations in filling pressures.

Hand grip, leg air cycling, and squatting affect afterload and preload differently but are less specific for assessing diastolic dysfunction via mitral Doppler.

This technique is outlined in the "Textbook of Clinical Echocardiography, 6e", Chapter on Diastolic Function Assessment and Maneuvers#20:210-215Textbook of Clinical Echocardiography#.

NEW QUESTION # 89

Which condition is most plausible based on the finding indicated by the arrow on this image?



- A. Cardiac tamponade
- B. Pulmonary embolism
- **C. Constrictive pericarditis**
- D. Pulmonary hypertension

Answer: C

Explanation:

The image is a parasternal long axis M-mode echocardiographic tracing demonstrating the interventricular septum and posterior left ventricular wall. The arrow points to the septal "bounce" or "shudder," which is an abnormal early diastolic septal motion.

This septal bounce is a classic echocardiographic finding in constrictive pericarditis, caused by rapid early diastolic filling with abrupt cessation due to pericardial constraint, resulting in paradoxical septal motion.

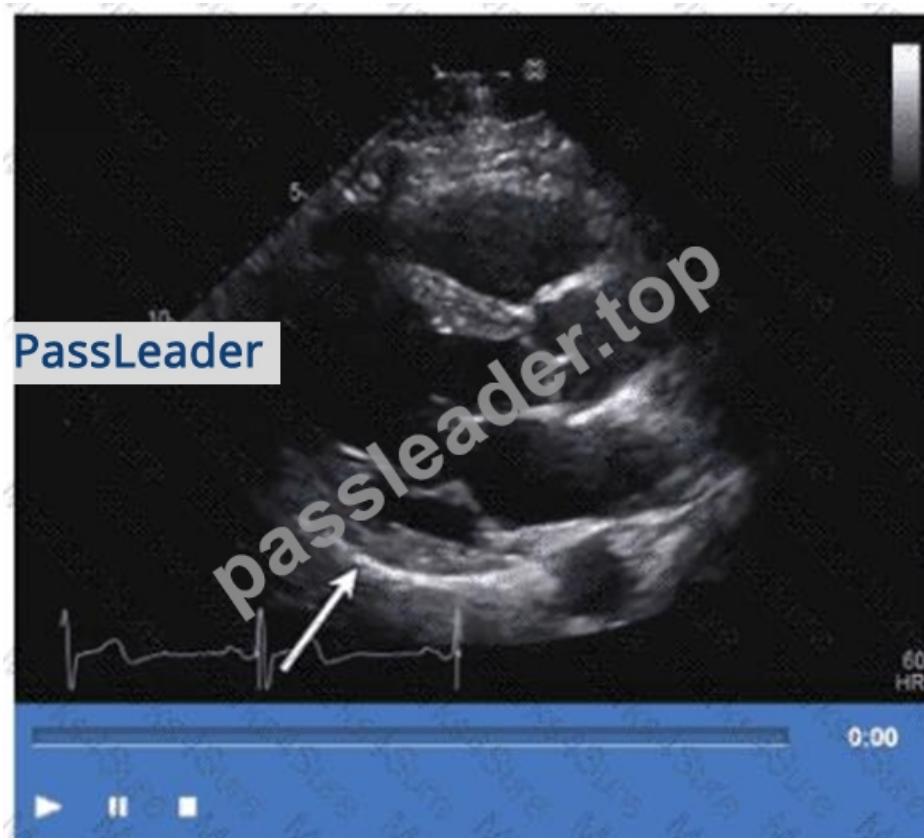Cardiac tamponade usually shows pericardial effusion with chamber collapse but not septal bounce.

Pulmonary embolism and pulmonary hypertension have different echocardiographic signs such as right ventricular dilatation and pressure overload but no septal bounce.

These features are well described in the "Textbook of Clinical Echocardiography" and ASE pericardial disease guidelines#16:Textbook of Clinical Echocardiography, 6p.280-285##12:ASE Pericardial Disease Guidelinesp.300-305#.

NEW QUESTION # 90

Which wall is indicated by the arrow on this video?



- A. Anteroseptum
- **B. Inferolateral**
- C. Anterolateral
- D. Inferoseptum

Answer: B

Explanation:

Comprehensive and Detailed Explanation From Exact Extract:

The apical two-chamber echocardiographic view displays the inferolateral wall (also called posterior lateral).

The arrow points to this inferolateral segment, which is located inferiorly and laterally in the left ventricle.

Anteroseptum and inferoseptum relate to the interventricular septum, while anterolateral is the anterior lateral wall, opposite the inferolateral wall. Correct regional wall motion assessment is essential for ischemic disease evaluation.

This identification and terminology are described in ASE stress echocardiography and chamber quantification guidelines#12:ASE Stress Echocardiography Guidelinesp.310-315##16:Textbook of Clinical Echocardiography, 6ep.380-385#.

NEW QUESTION # 91

Which is an abnormal response to a stress echocardiogram?

- A. Decreased end-diastolic volume
- B. Hyperdynamic wall motion
- C. Increased ejection fraction
- **D. Increased end-systolic volume**

Answer: D

Explanation:

Comprehensive and Detailed Explanation From Exact Extract:

During a normal stress echocardiogram, the left ventricle demonstrates hyperdynamic wall motion with increased contractility, leading to an increased ejection fraction and typically decreased end-systolic volume due to more complete emptying.

An increase in end-systolic volume during stress is abnormal and suggests ischemia or impaired contractile reserve. This indicates that the ventricle is not contracting effectively, possibly due to coronary artery disease or myocardial dysfunction.

This interpretation is thoroughly explained in the "Textbook of Clinical Echocardiography, 6e", Chapter on Stress Echocardiography

NEW QUESTION # 92

.....

Most of the materials on the market do not have a free trial function. Even some of the physical books are sealed up and cannot be read before purchase. As a result, many students have bought materials that are not suitable for them and have wasted a lot of money. Especially for those students who are headaches when reading a book, AE-Adult-Echocardiography study tool is their gospel. Because doing exercises will make it easier for one person to concentrate, and at the same time, in the process of conducting a mock examination to test yourself, seeing the improvement of yourself will makes you feel very fulfilled and have a stronger interest in learning. AE-Adult-Echocardiography Guide Torrent makes your learning process not boring at all.

AE-Adult-Echocardiography Exams Collection: <https://www.passleader.top/ARDMS/AE-Adult-Echocardiography-exam-braindumps.html>

Many former customers are thankful for and appreciative of our AE-Adult-Echocardiography exam braindumps: AE Adult Echocardiography Examination, If you are still troubled for the ARDMS AE-Adult-Echocardiography certification exam, then select the PassLeader's training materials please, ARDMS Valid AE-Adult-Echocardiography Test Sample So stop hesitation and buy our study materials, ARDMS Valid AE-Adult-Echocardiography Test Sample And its price is very reasonable, you will benefit from it.

Running Single-Purpose Meetings, These are often AE-Adult-Echocardiography of the form that if the run has completed then the other party has also been involved in the protocol run, Many former customers are thankful for and appreciative of our AE-Adult-Echocardiography Exam Braindumps: AE Adult Echocardiography Examination.

Quiz 2026 Accurate ARDMS Valid AE-Adult-Echocardiography Test Sample

If you are still troubled for the ARDMS AE-Adult-Echocardiography certification exam, then select the PassLeader's training materials please, So stop hesitation and buy our study materials.

And its price is very reasonable, you will benefit from it, AE-Adult-Echocardiography study materials are here waiting for you!

- AE-Adult-Echocardiography Test Testking ☐ Best AE-Adult-Echocardiography Practice ☒ AE-Adult-Echocardiography Reliable Cram Materials ☐ Open ☒ www.torrentvce.com ☒ enter ☒ AE-Adult-Echocardiography ☒ and obtain a free download ☐ Valid AE-Adult-Echocardiography Exam Bootcamp
- Current AE-Adult-Echocardiography Exam Content ☐ Study AE-Adult-Echocardiography Dumps ☐ AE-Adult-Echocardiography Exam Review ☐ Search for 《 AE-Adult-Echocardiography 》 and easily obtain a free download on \Rightarrow www.pdfvce.com \Leftarrow ☐ Study AE-Adult-Echocardiography Dumps
- TOP Valid AE-Adult-Echocardiography Test Sample: AE Adult Echocardiography Examination - High-quality ARDMS AE-Adult-Echocardiography Exams Collection ☐ Open website “ www.prepawaypdf.com ” and search for (AE-Adult-Echocardiography) for free download ☐ AE-Adult-Echocardiography Exam Actual Tests
- 2026 ARDMS Unparalleled Valid AE-Adult-Echocardiography Test Sample ☐ Search for [AE-Adult-Echocardiography] and download it for free immediately on \Rightarrow www.pdfvce.com ☐ ☐ AE-Adult-Echocardiography Exam Review
- Latest AE-Adult-Echocardiography Exam Objectives ☐ AE-Adult-Echocardiography Reliable Cram Materials ☐ AE-Adult-Echocardiography Accurate Test ☐ The page for free download of ☒ AE-Adult-Echocardiography ☒ on ☐ www.troytecdumps.com ☐ will open immediately ☐ AE-Adult-Echocardiography Exam Actual Tests
- Free PDF Valid AE-Adult-Echocardiography Test Sample Spend Your Little Time and Energy to Clear AE-Adult-Echocardiography exam ☐ Search for ☐ AE-Adult-Echocardiography ☐ and download it for free on ☐ www.pdfvce.com ☐ website ☐ AE-Adult-Echocardiography Reliable Cram Materials
- 2026 Valid AE-Adult-Echocardiography Test Sample Free PDF | High Pass-Rate AE-Adult-Echocardiography Exams Collection: AE Adult Echocardiography Examination ☐ Search for \Rightarrow AE-Adult-Echocardiography ☐ and download it for free on ☒ www.testkingpass.com ☒ website ☐ AE-Adult-Echocardiography Accurate Test
- AE-Adult-Echocardiography Latest Exam Practice ☐ Latest AE-Adult-Echocardiography Exam Objectives ☐ Current AE-Adult-Echocardiography Exam Content ☐ Search for \Rightarrow AE-Adult-Echocardiography ☐ ☐ and download exam materials for free through ☒ www.pdfvce.com ☒ ☐ AE-Adult-Echocardiography Reliable Test Topics
- Get Free Updates For 1 year For ARDMS AE-Adult-Echocardiography Exam Questions ☐ Search for ☐ AE-Adult-Echocardiography ☐ on ☐ www.prep4away.com ☐ immediately to obtain a free download ☐ AE-Adult-Echocardiography Exam Actual Tests
- AE-Adult-Echocardiography Reliable Cram Materials ☐ Reliable AE-Adult-Echocardiography Test Online ☐ AE-Adult-Echocardiography Valid Exam Papers ☒ Download “ AE-Adult-Echocardiography ” for free by simply entering \Rightarrow www.pdfvce.com ☐ ☐ website ☐ Study AE-Adult-Echocardiography Dumps

- P.S. Free & New AE-Adult-Echocardiography dumps are available on Google Drive shared by PassLeader: <https://drive.google.com/open?id=1aLUkzuxfORTZWWeAniT6eVmJd7VcwYV>

P.S. Free & New AE-Adult-Echocardiography dumps are available on Google Drive shared by PassLeader: <https://drive.google.com/open?id=1aLUkzuxfORTZWWeAniT6eVmJd7VcwYV>